

EYE CANDY - ELEVATING BEAUTY AND FUNCTION WITH OCULAR AESTHETICS

Selina McGee, OD, FAAO
Cory J. Lappin, OD, MS, FAAO



FINANCIAL DISCLOSURES FOR CORY J. LAPPIN, OD, MS, FAAO

Bausch + Lomb

Dompé

Lumenis

Myze

NuLids

PRN Vision Group

Tarsus Pharmaceuticals

Vital Tears

The content of this COPE accredited course was prepared independently. The authors have received no financial or commercial support for this presentation. All relevant relationships have been mitigated.

FINANCIAL DISCLOSURES FOR SELINA R. MCGEE, OD, FAAO

Allergan-Speaker/Consultant

Alderya-Consultant

Avellino-Consultant

Bausch & Lomb-Speaker/Consultant

Bruder-Consultant

CynoSure-Speaker/Consultant

Dompe-Speaker/Consultant

Eyevance-Consultant

Horizon-Consultant

Lumenis-Speaker/Consultant

Ocuphire-Consultant

Optovue Speaker/Consultant All financial relationships have been mitigated.

Osmotica-Speaker/Consultant

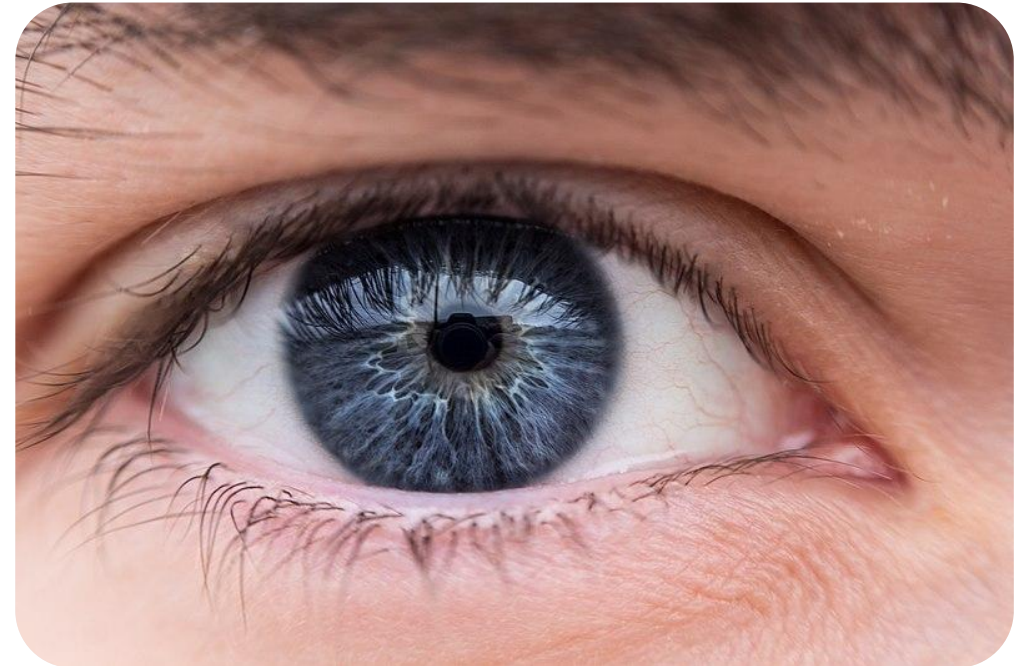MORE THAN JUST VISION...

Vision considered to be most precious sense

- Blindness feared more than premature death

Eyes do more than provide vision

- Social cues and interaction
- Considered most attractive part of face for both men and women
- Self-perception
 - Confidence
 - Quality of life



Saltov K. Human eye iris 5. Wikimedia Commons. CC BY 4.0. <https://commons.wikimedia.org/w/index.php?curid=78106967>. Published October 17, 2017. Accessed September 3, 2021.

THE OCULAR SURFACE

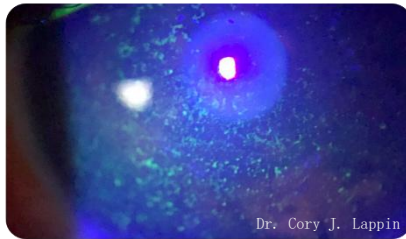
Function of the ocular surface

- Protection
- Visual function
- Tear production and secretion

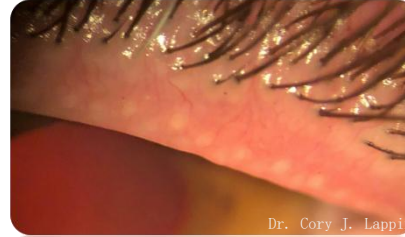
NOT just for adornment



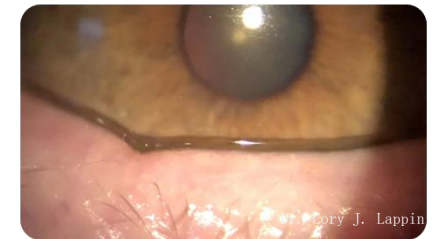Challenges to the ocular surface



➔ **Dry eye**

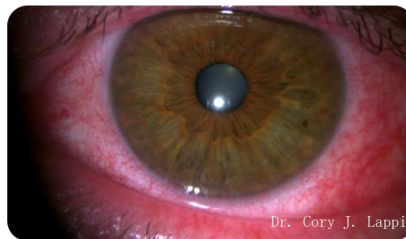

➔ **MGD**

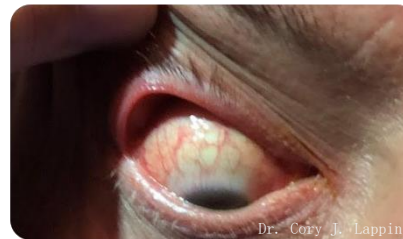

➔ **Blepharitis**

- Bacterial
- Demodex

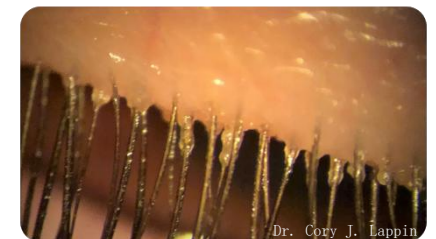

➔ **Rosacea**



➔ **Eyelid disorders**

- Ptosis
- Lid laxity
- Lagophthalmos
- Ectropion/Entropion



➔ **Lash changes**

- Madarosis
- Trichiasis

COSMETIC CONCERNS

Eyelids

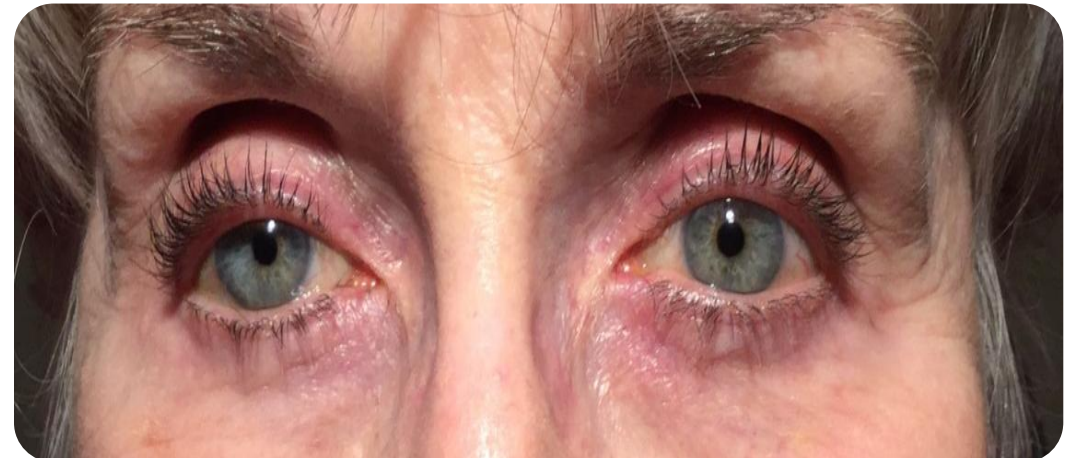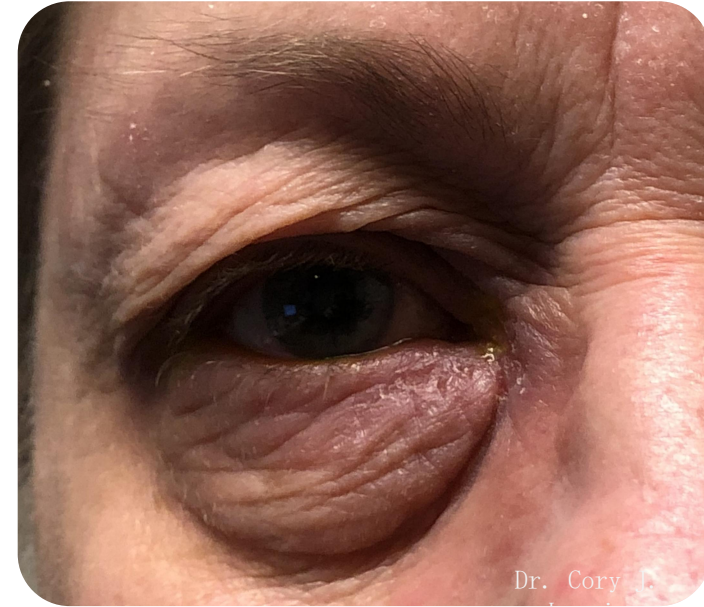- “Saggy” or “droopy”
- “Bags” under eyes
- Dark Circles

Lashes

- Lash loss, misdirection, thinning

Appearance

- Redness
- Glassy
- “Tired”



WHAT ABOUT THESE CIRCLES?

Dark Circles

Etiology and Management Options

Daniel P. Friedmann, MD^{a,*}, Mitchel P. Goldman, MD^{b,c}

		Treatment Option
Hollowing/ shadowing	Age-related infraorbital skin laxity and volume loss SOOF pseudoherniation Orbicularis oculi muscle hypertrophy	Hyaluronic acid filler Fractional ablative CO ₂ laser resurfacing
Excessive pigmentation	Periorbital melanosis (“constitutional type”, may be an extension of pigmentary demarcation lines) ¹⁰ Postinflammatory hyperpigmentation (allergic contact dermatitis, atopic dermatitis) Melasma Oculodermal melanocytoses (bilateral nevus of Ota-like macules) Rare: Acanthosis nigricans, fixed drug eruptions, and erythema dyschromium perstans	IPL Q-switched laser Nonablative fractionated resurfacing
Prominent vasculature	Thin, translucent skin Excess subcutaneous vascularity Venous stasis	Long-pulsed laser IPL Hyaluronic acid filler Fractional ablative CO ₂ laser resurfacing
Exogenous	Penicillamine-induced periorbital pigmentation Bimatoprost-induced periorbital hollowing and hyperpigmentation	Hyaluronic acid filler Fractional ablative CO ₂ laser resurfacing

FUNCTIONAL CONCERNS

Vision

- Fluctuation
- Restricted field of vision

Tear Film

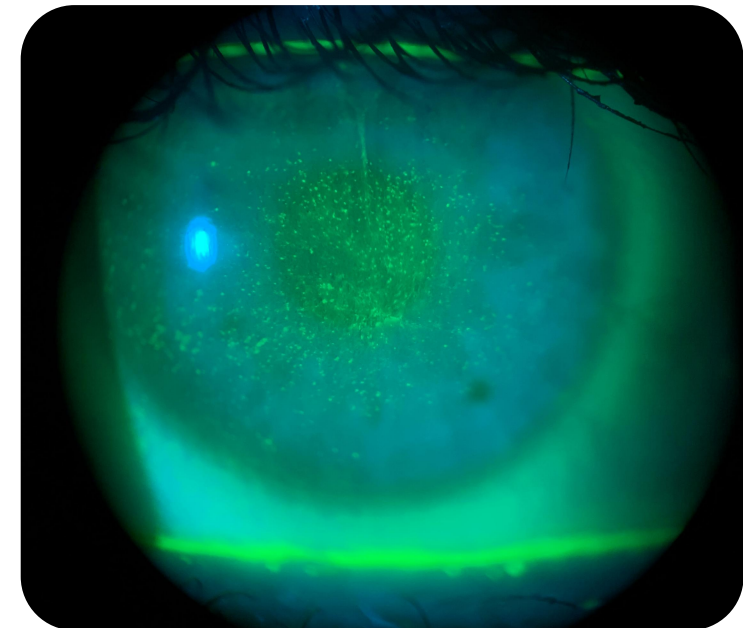
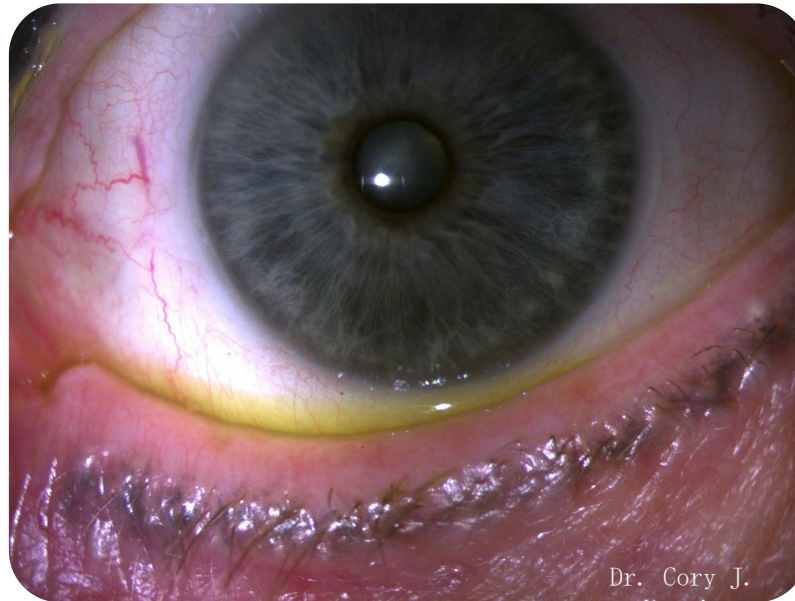
- Instability


Protection

- Impaired blinking
- Exposure

Inflammation

- Redness





TREATMENT OPTIONS



CONVERSATIONS

Omega fatty acid supplementation

- Functional and cosmetic benefits

Lid hygiene

- Hypochlorous acid
- Okra

Removing Bad Actors and Offenders

Eliminating Harmful Habits

Warm and cool compresses

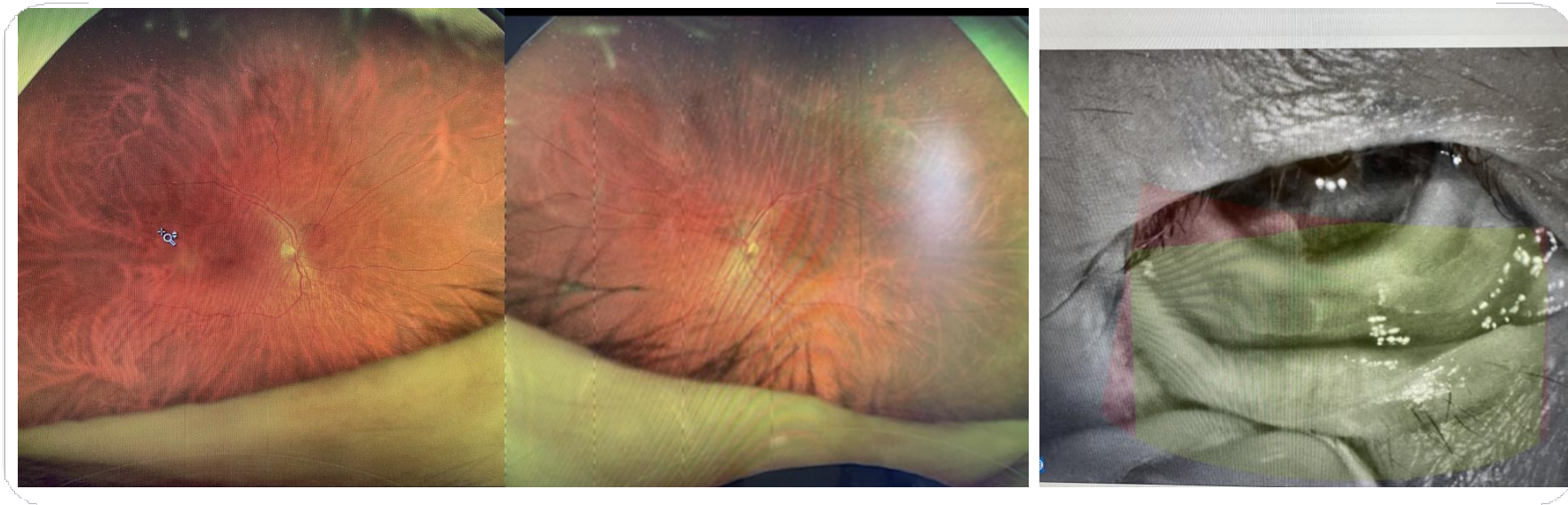
Preservative-free lubricating drops to support the ocular surface

Visual Hygiene Practices



Sem J. Fish oil capsules. CC BY 2.0, www.semtrio.com. Published September 12, 2018. Accessed December 18, 2021

EYELIDS



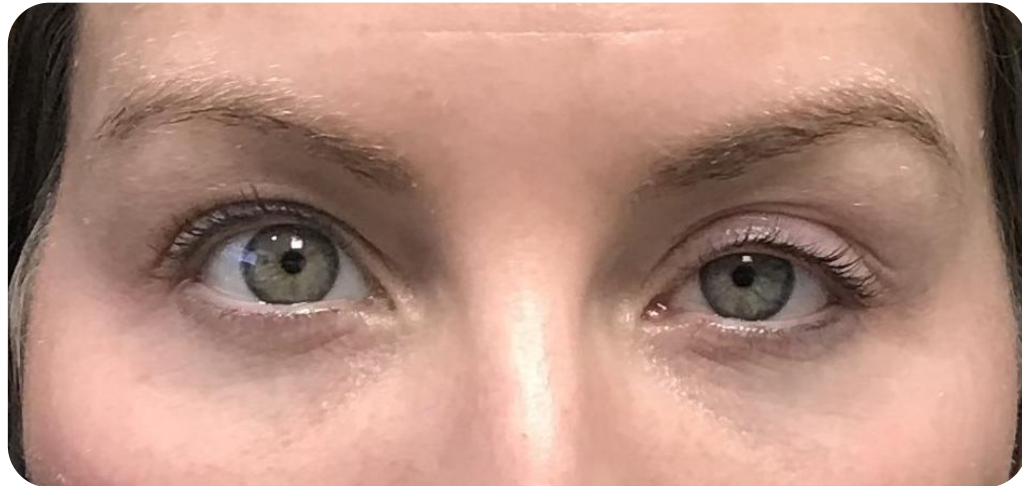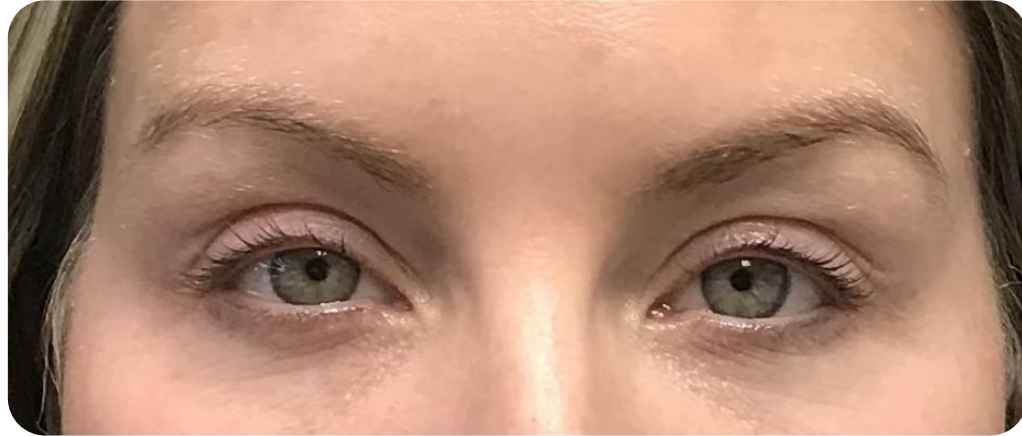EYELIDS

Prescription

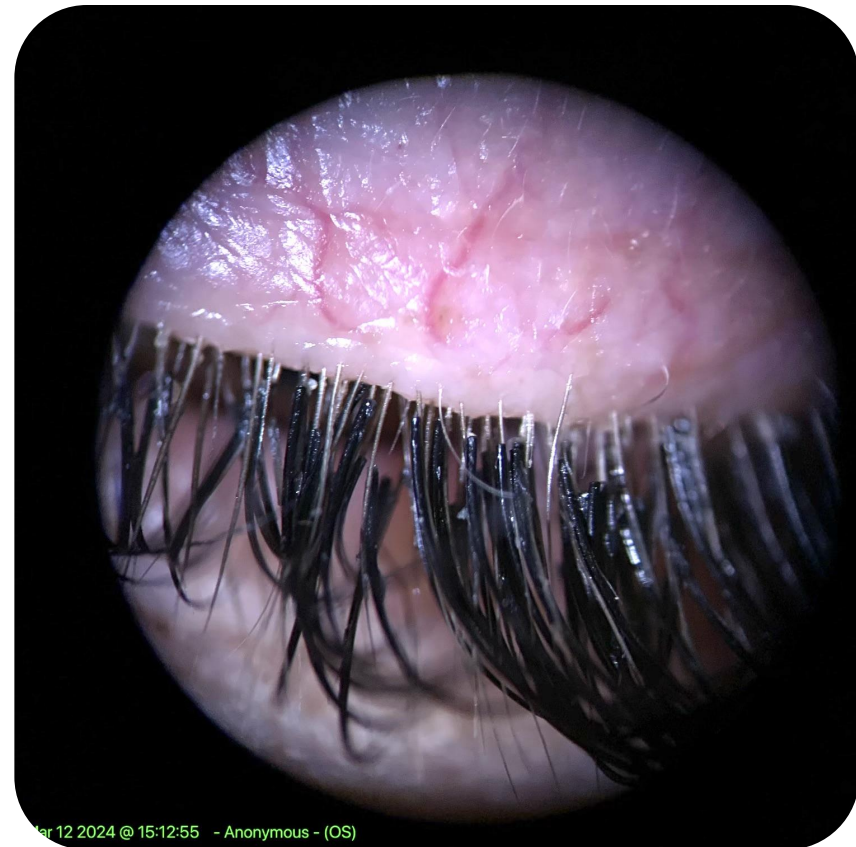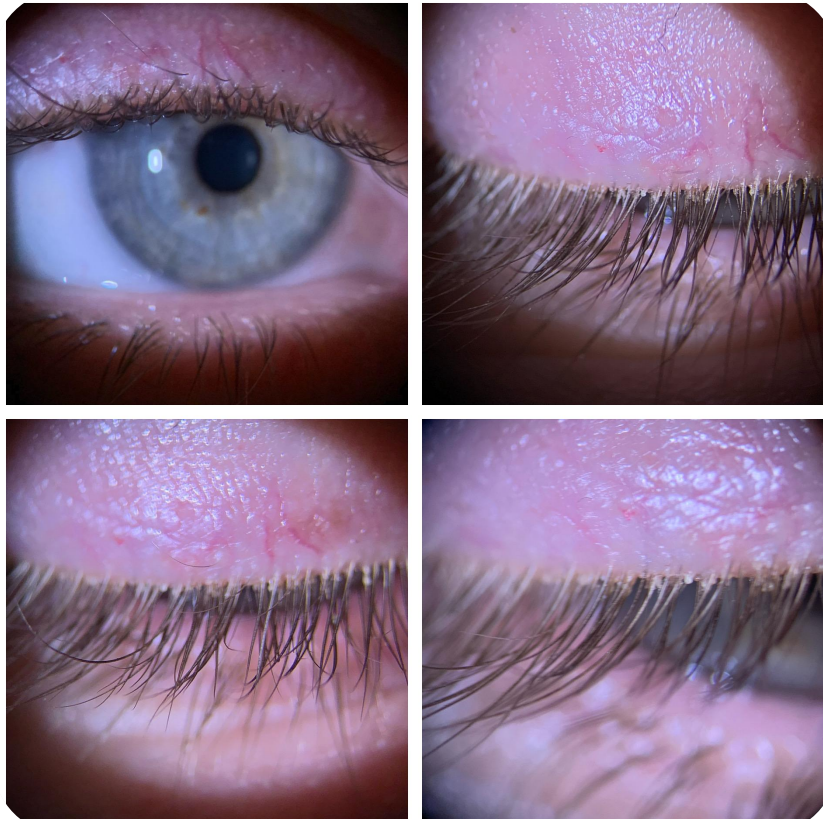
- Oxymetazoline (Upneeq)

Surgery

- Blepharoplasty



ASSESSMENT



Mar 12 2024 @ 15:12:55 - Anonymous - (OS)

LASHES

Growth serums

- Caution with PGAs
- Safer alternatives

Lash Extensions

- Allergy
- Hygiene concerns

Lash Tint & Lift



EYELASH SERUMS

Latisse-only FDA approved lash serum

- Active ingredient

Synthetic prostaglandins

- Isopropyl cloprostenate

Ptosis

Relative Enophthalmos

Inferior Scleral Show

Periorbital Fat Atrophy

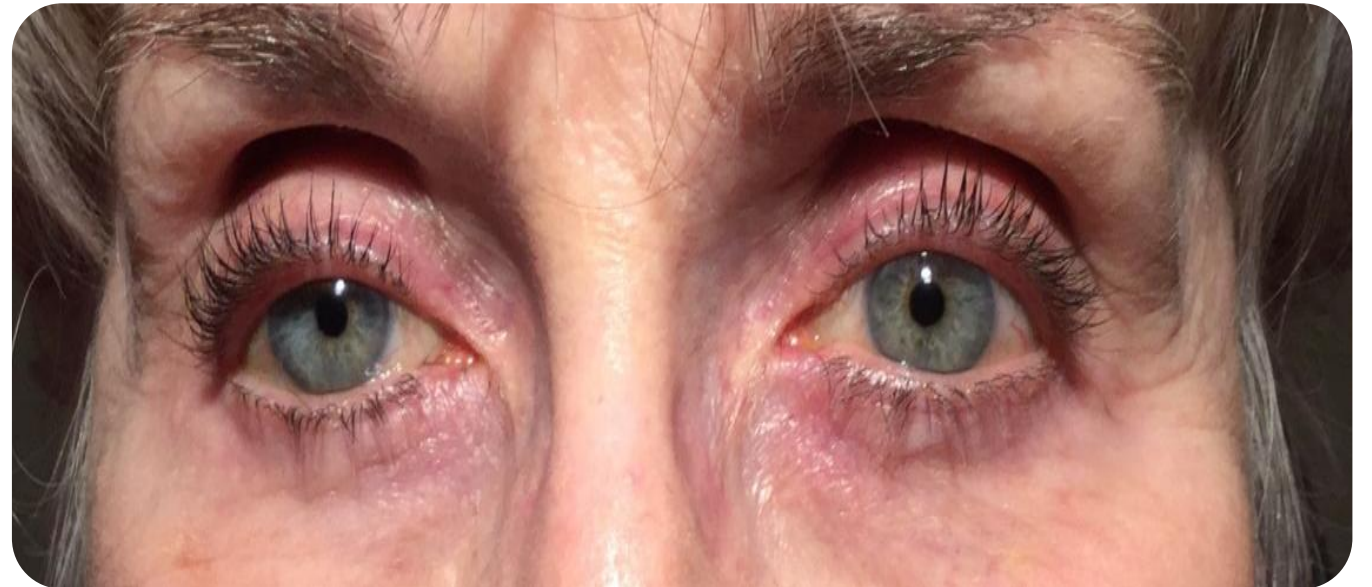Involution of dermatochalasis

Meibomian Gland Dysfunction

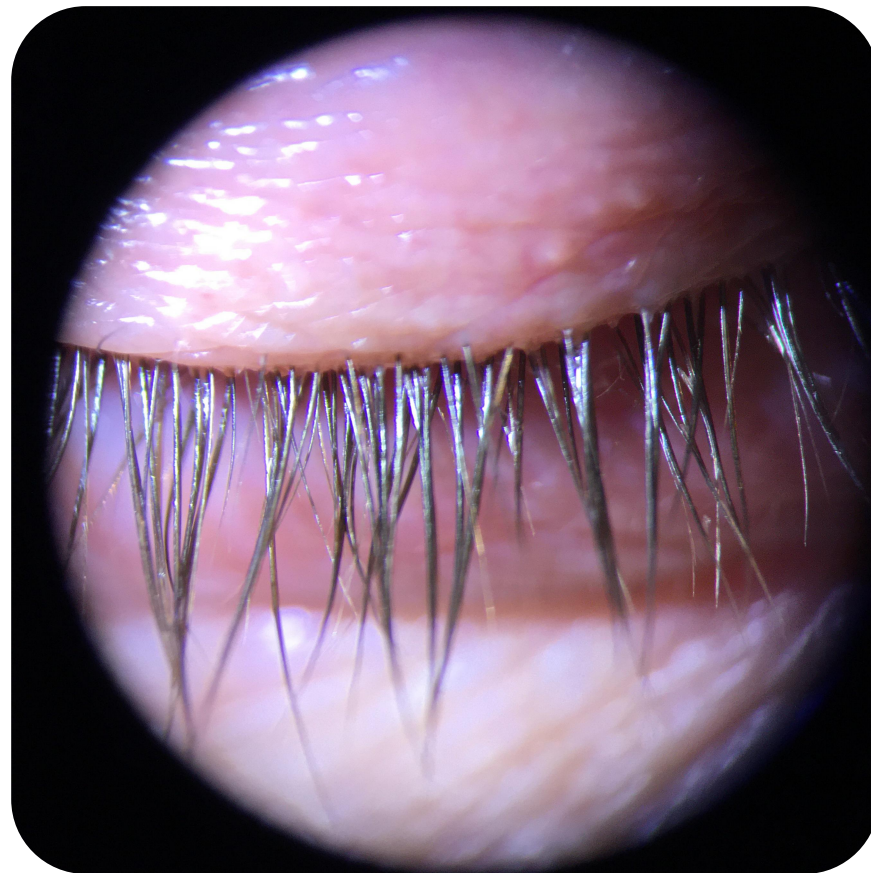
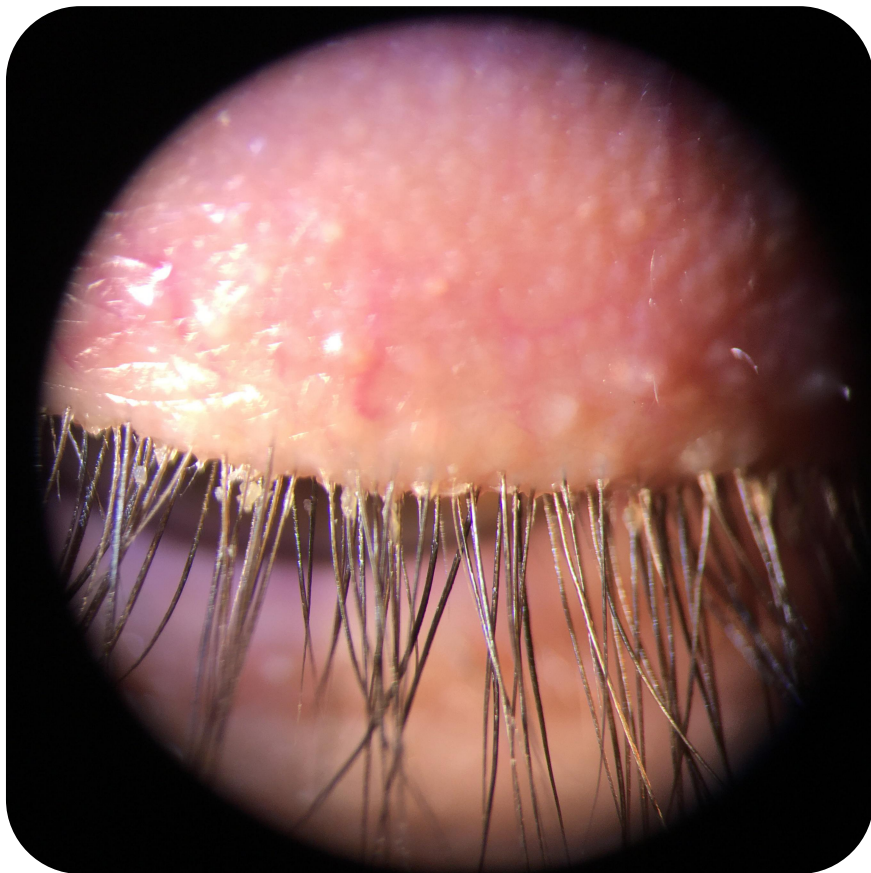Hyperpigmentation

Redness

Pruritus



LOTILANER 0.25% AT 6 WEEKS



CONJUNCTIVA

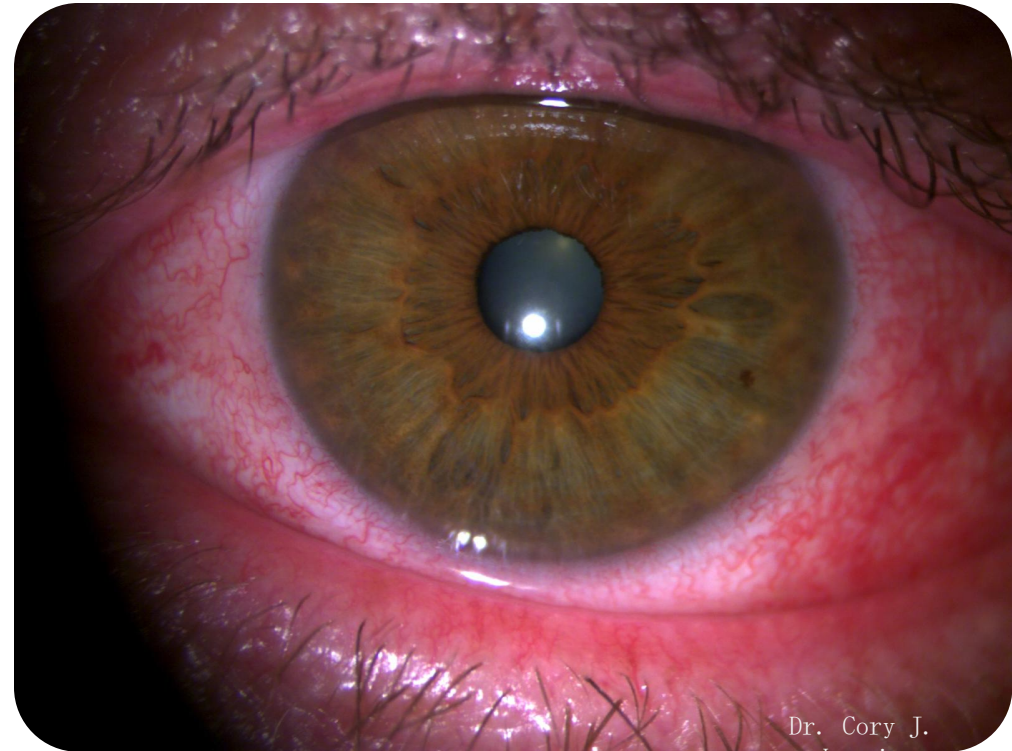
Vasoconstrictors

- Brimonidine (Lumify)
- Tetrahydrozoline (Visine) and naphazoline (ClearEyes)
 - Rebound redness

“Eye whitening” procedures

- “Brite White”
- **AVOID!!**

Still need to address root cause



Dr. Cory J.
Lappin

COSMETICS

Controversial

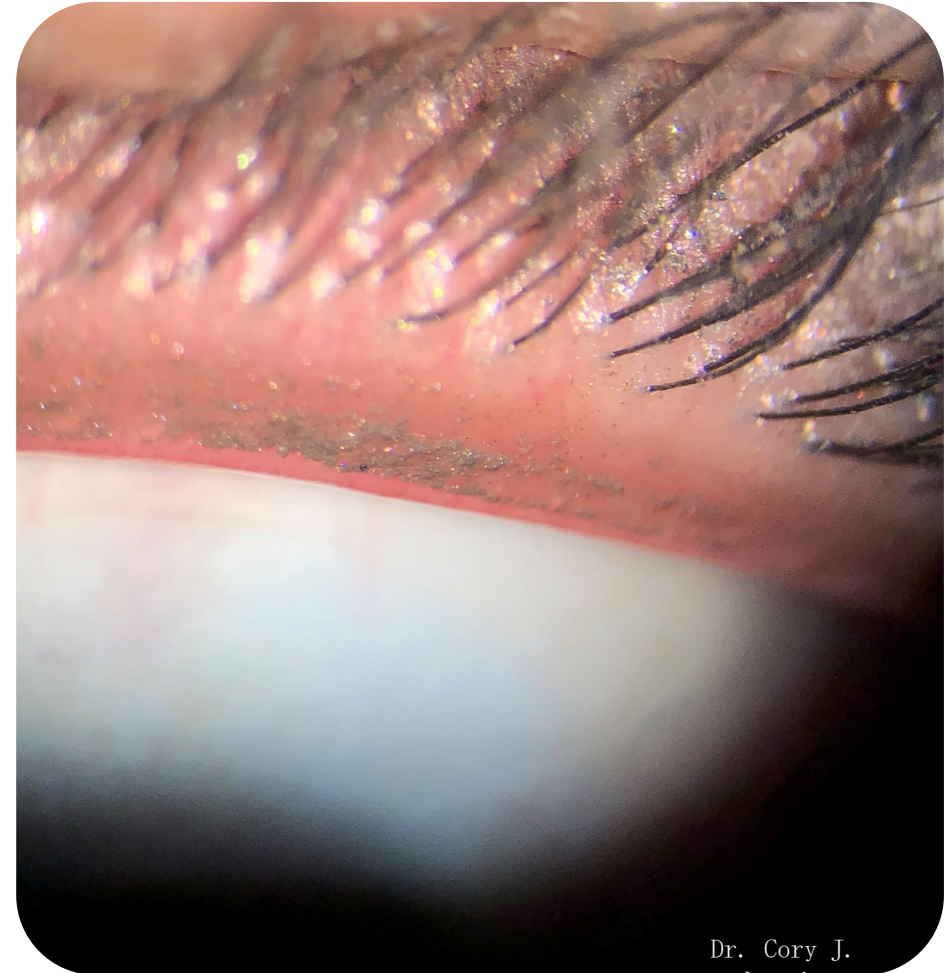- Evolving understanding

Preservatives

- Not all the same

Retinol

- May negatively impact meibomian glands



COSMETICS?

❖ Cosmetics-As defined by the FDA: Product intended to be applied to the human body for cleansing, beautifying, promoting attractiveness, or altering the appearance without affecting the body's structure or function

❖ Habits

❖ Lash Love

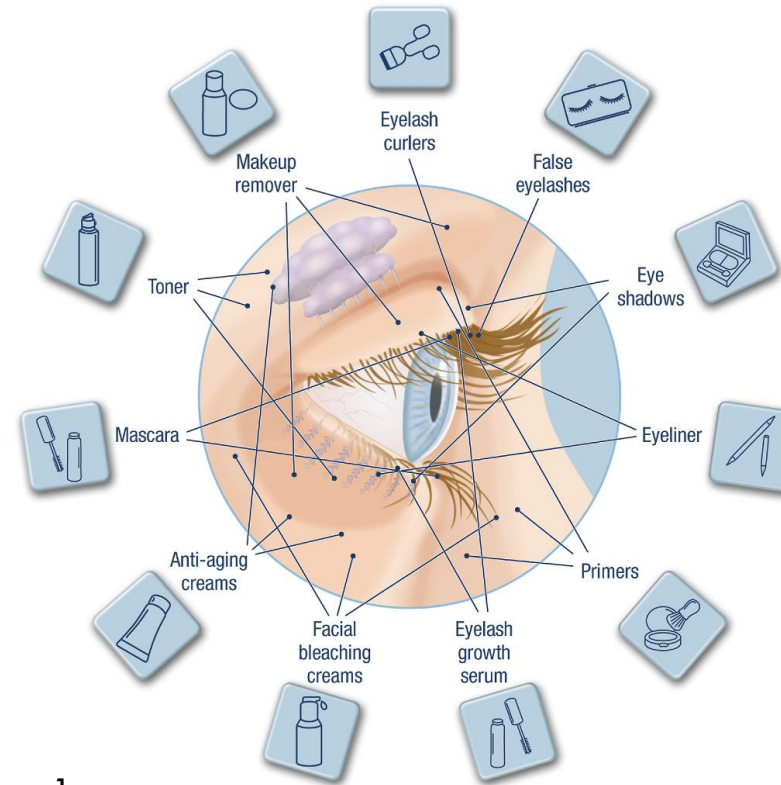


Figure 1:
TFOS Lifestyle: Impact of cosmetics on the ocular surface.
Sullivan et. al

USE THIS NOT THAT

Not this	This
Prostaglandin Analog-Isopropyl Cloprestonate	Polypeptide/Lipopeptide Lash Conditioner
Waterproof Mascara	Non-waterproof*
Glitter Eyeshadows	Shimmer/Matte Eyeshadows
Retinol-if dry eye dx then don't use. If no dry eye dx, then can use, but stay two finger widths away from eyelid margin to avoid migration-MUST USE SUNSCREEN	Caffeine, Vitamin C, Vitamin E, Ferulic, Hyaluronic Acid, Niacinimide 
False Lash Strips with Latex and Formaldehyde	Individual False lashes with non-formaldehyde and Latex lash glue
Eyelash Extensions	Individual False lashes with non-formaldehyde and Latex lash glue
Oil based eye-makeup remover cleansers	Micellar Water*
Eyeliners on the water line	Eyeliners on the dry side*

*Be mindful of ingredients

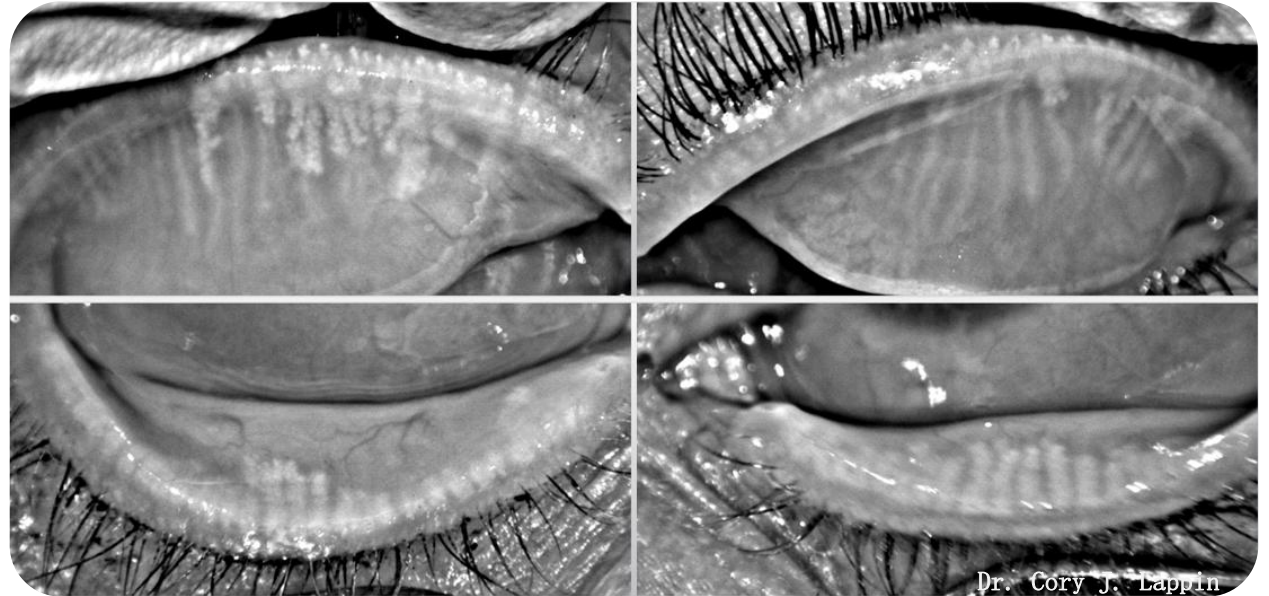
ORAL MEDICATIONS

Tetracyclines and macrolides

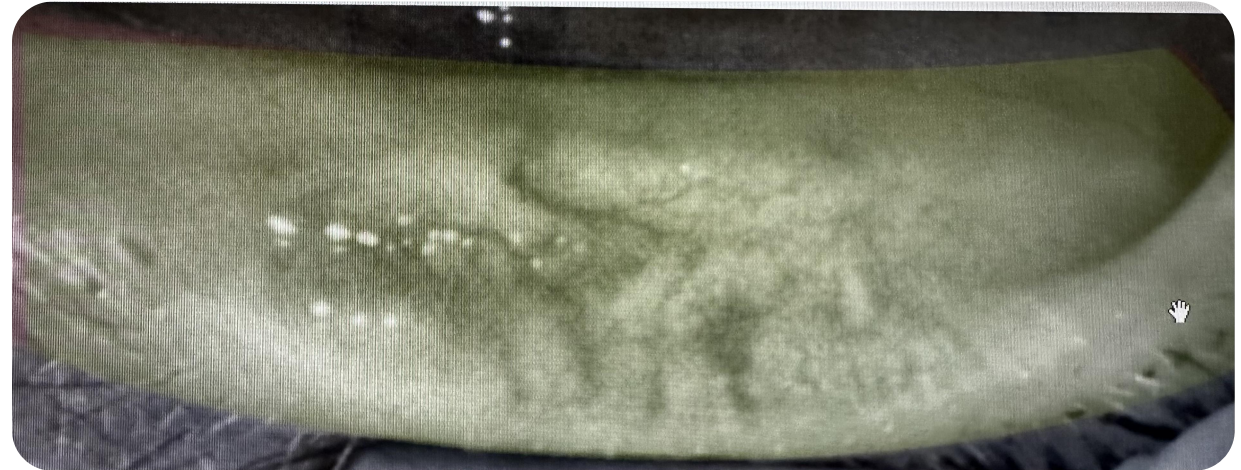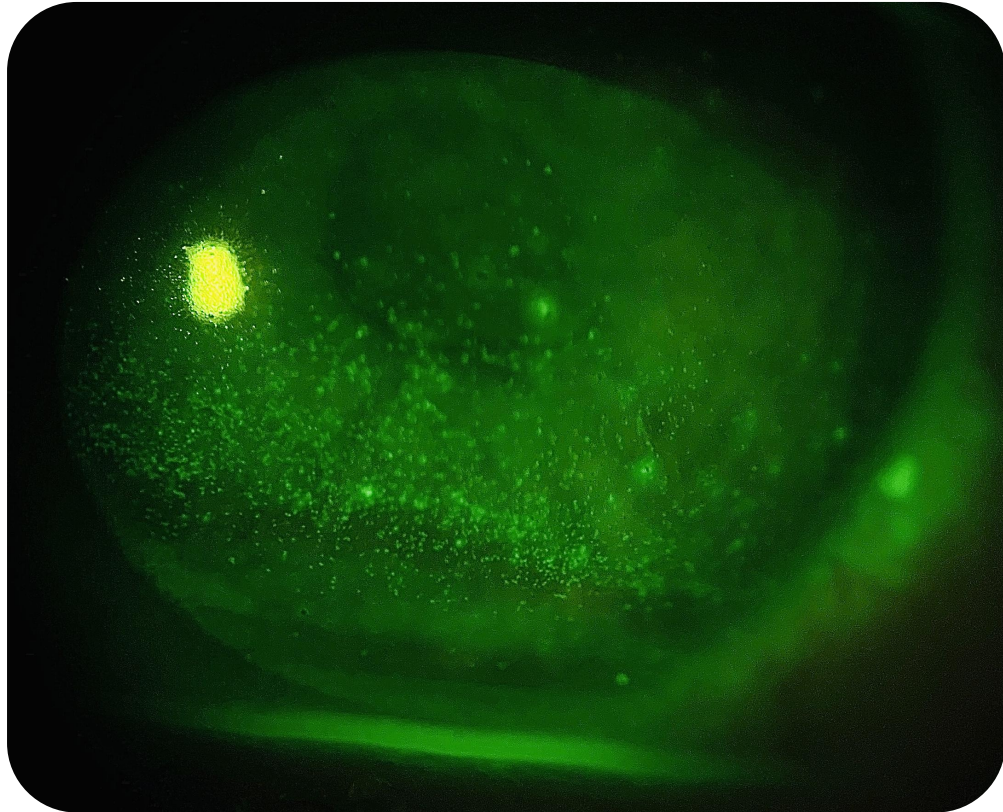
- Doxycycline
- Azithromycin


Isotretinoin (Accutane)

- May negatively impact meibomian glands



HOW OLD IS THIS PATIENT?





IN-OFFICE PROCEDURES

Merging beauty and function

INTENSE PULSED LIGHT (IPL)

Improves meibomian gland structure and function

Destroys telangiectatic vessels and decreases inflammation

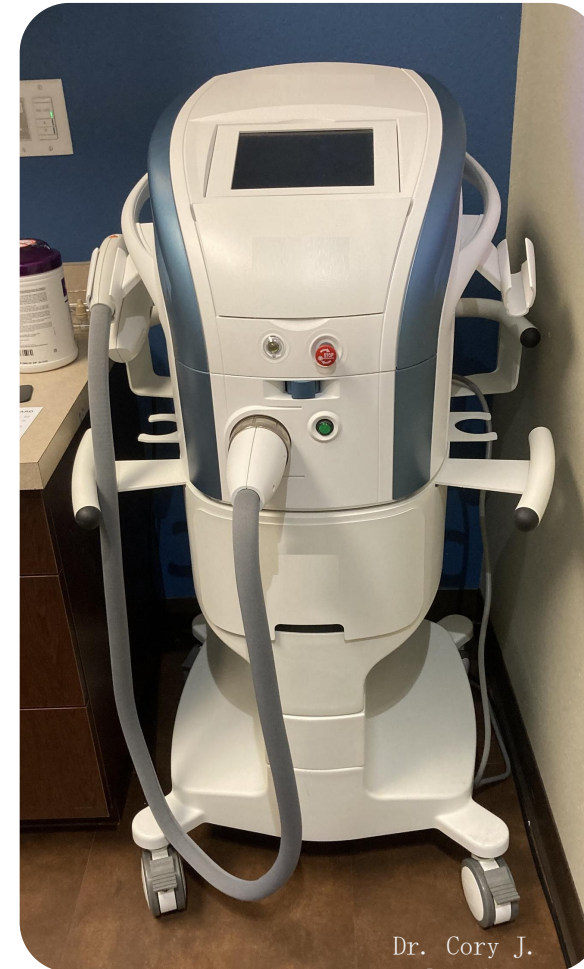- Improved redness

Improves skin quality

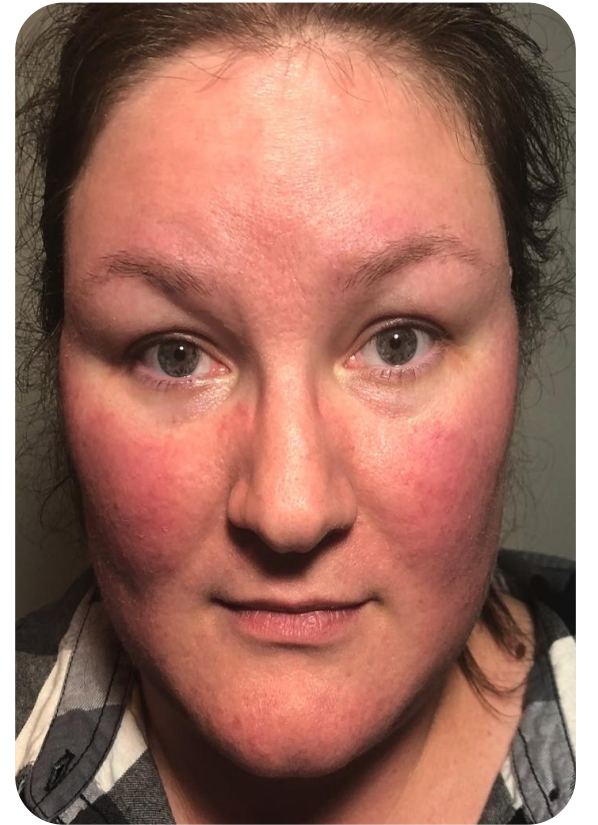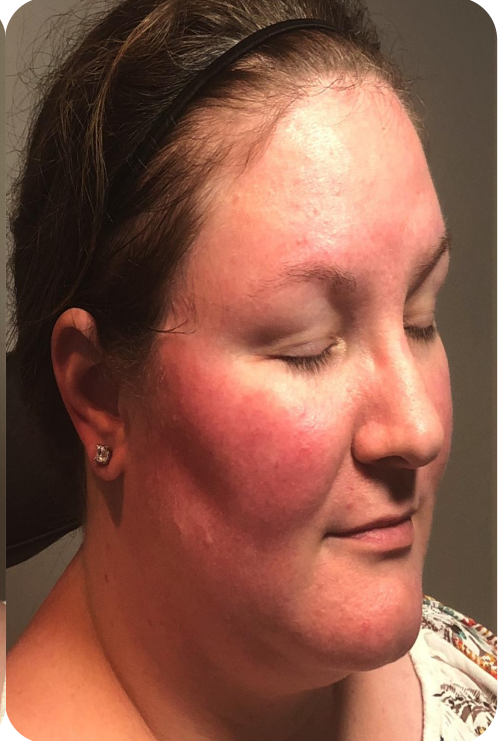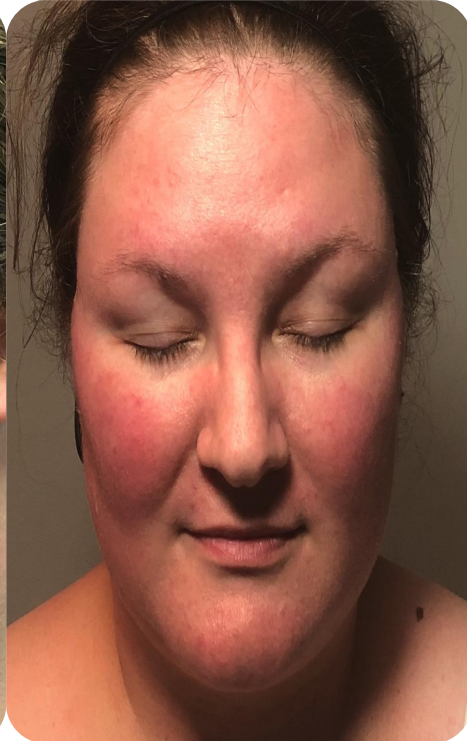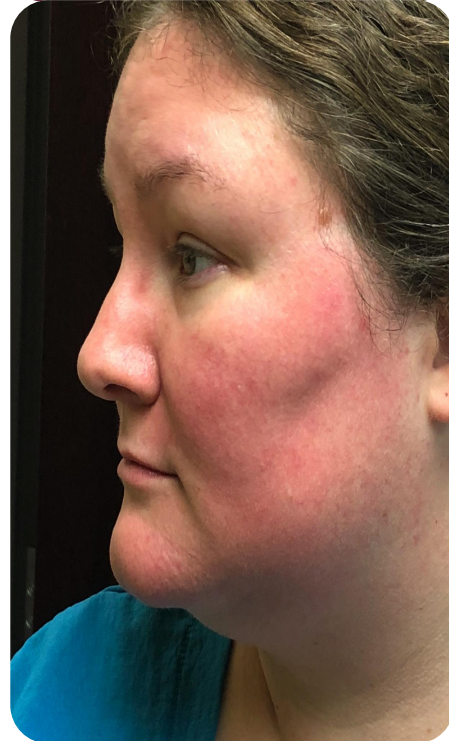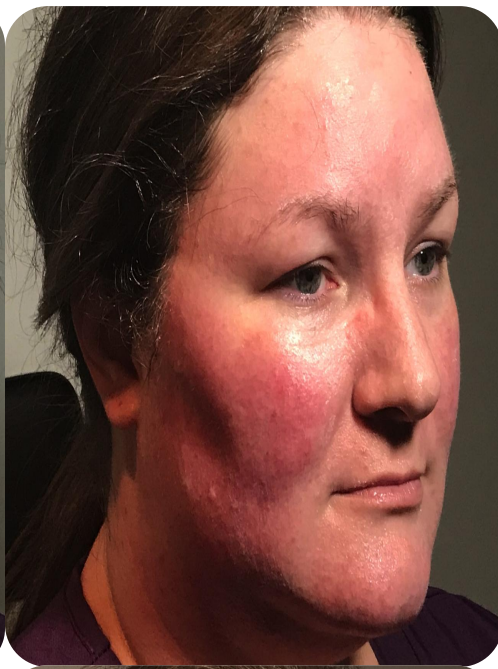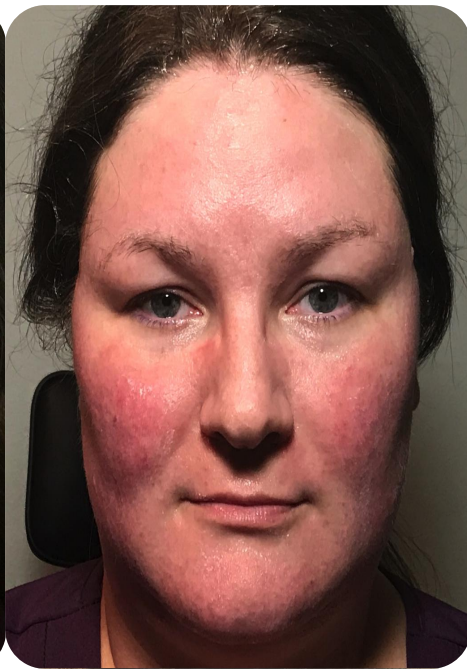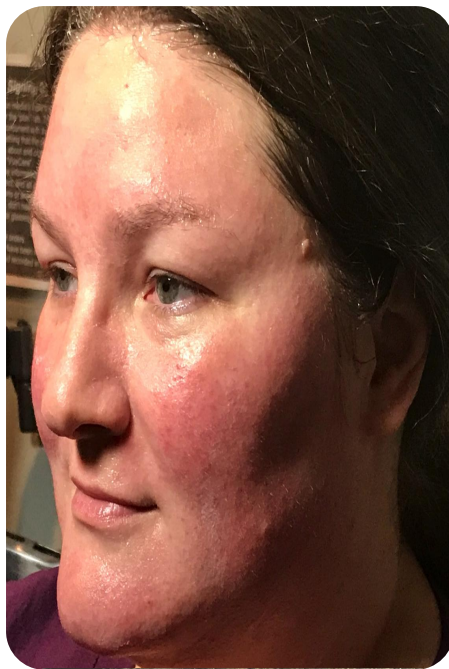- Repairs sun damage
- Promotes collagen synthesis

Lessens microbial burden on lids

Photobiomodulation



Dr. Cory J.
Lappin



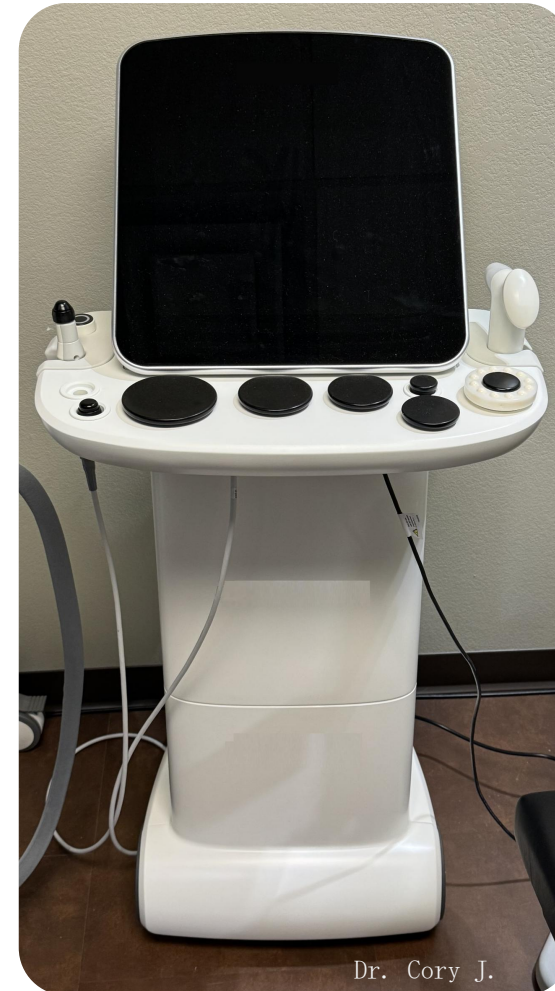RADIOFREQUENCY (RF)

Functional benefits

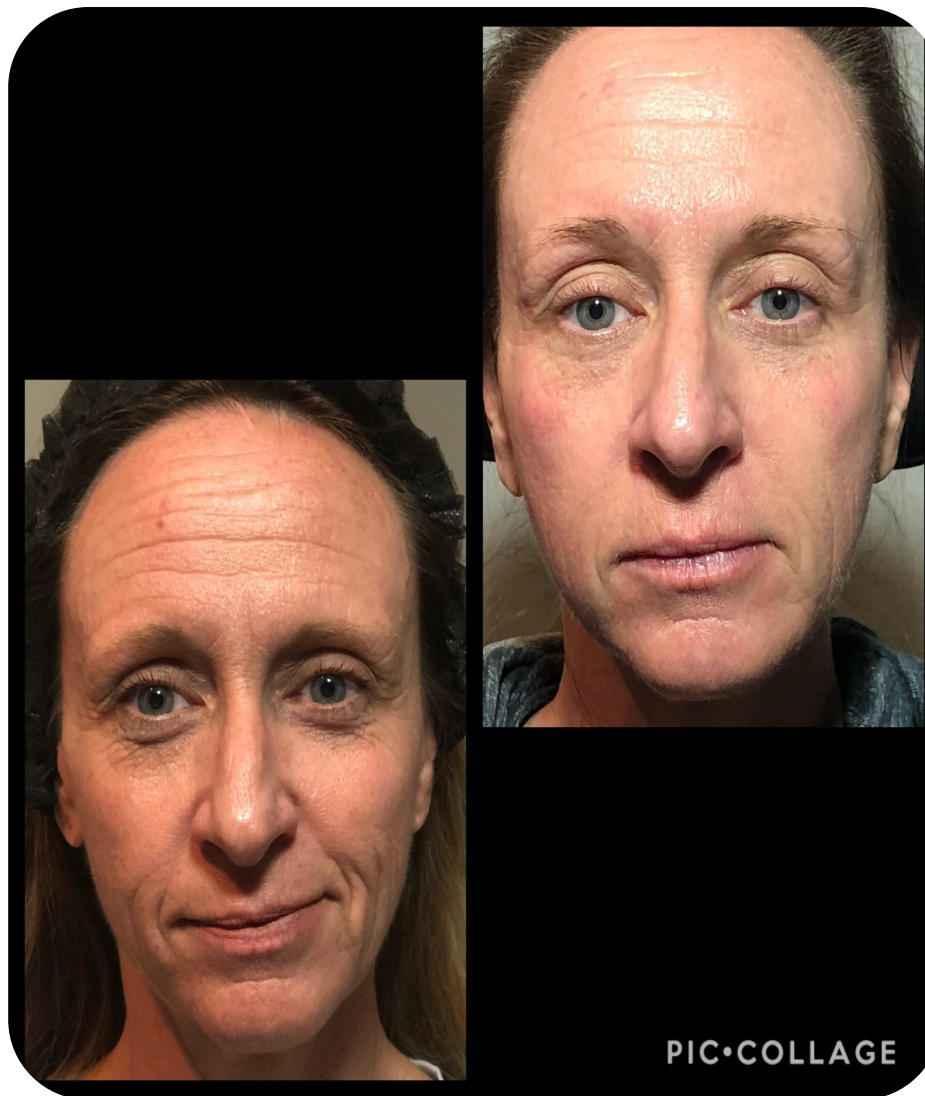- Improves meibomian gland function
 - Liquefies stagnant meibum
- Potentially improves blinking mechanics
 - Secondary to improved skin tone

Cosmetic benefits

- Reduces wrinkles and improves skin quality
- Stimulates collagen synthesis



RADIOFREQUENCY BEFORE & AFTER 4 TREATMENTS

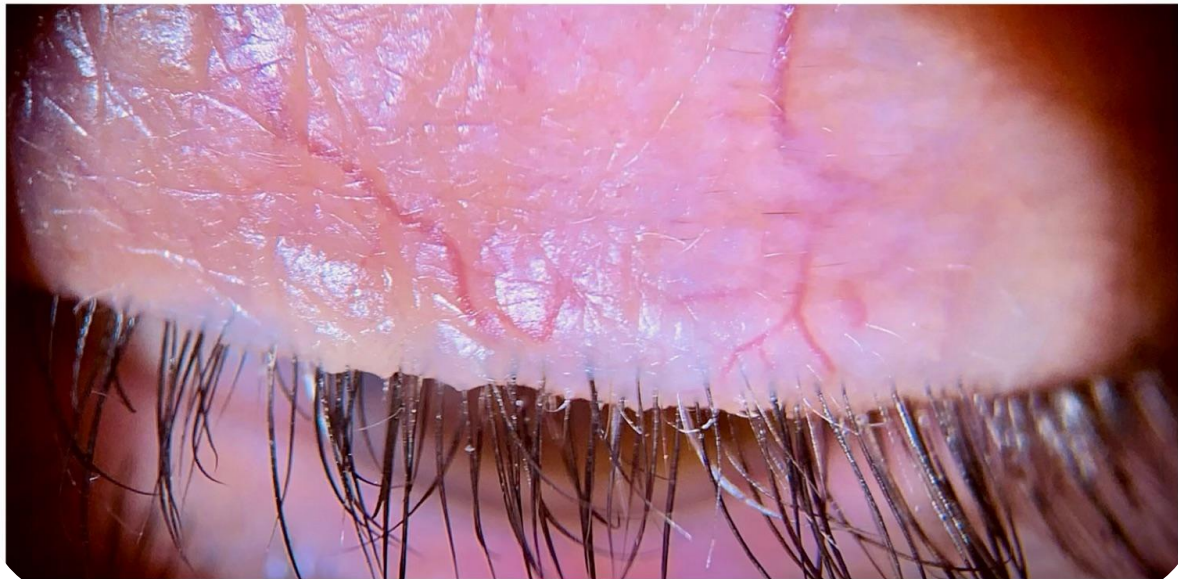
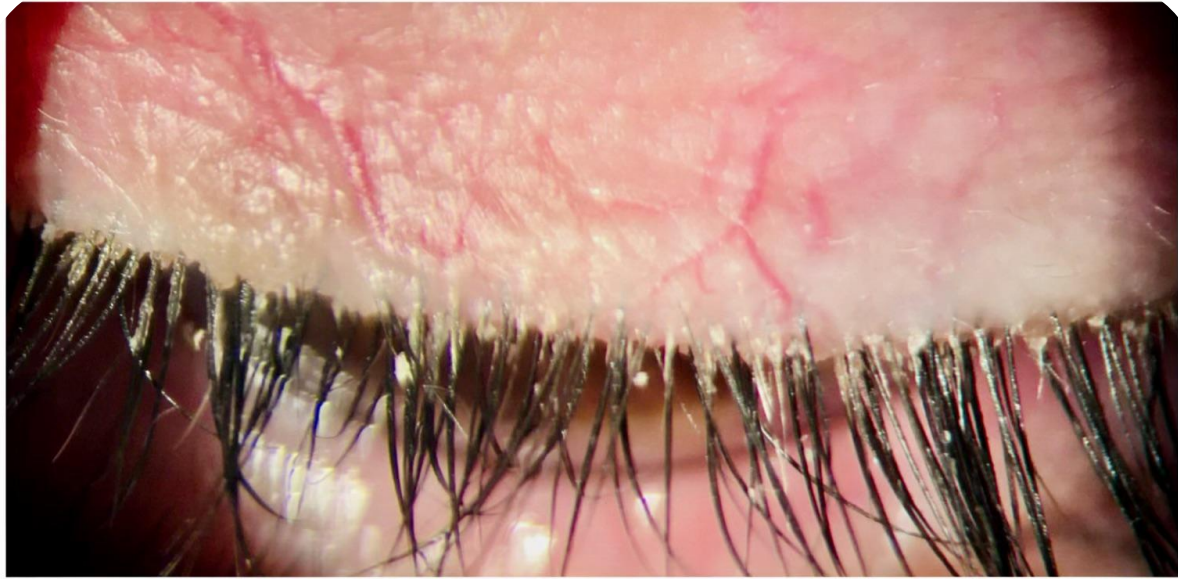


MICROBLEPHAROEXFOLIATION

Improves function and cosmetic appearance

- Removes proinflammatory debris and biofilm
 - Reduced redness
 - Cleans lashes and lid margin





INJECTIONS

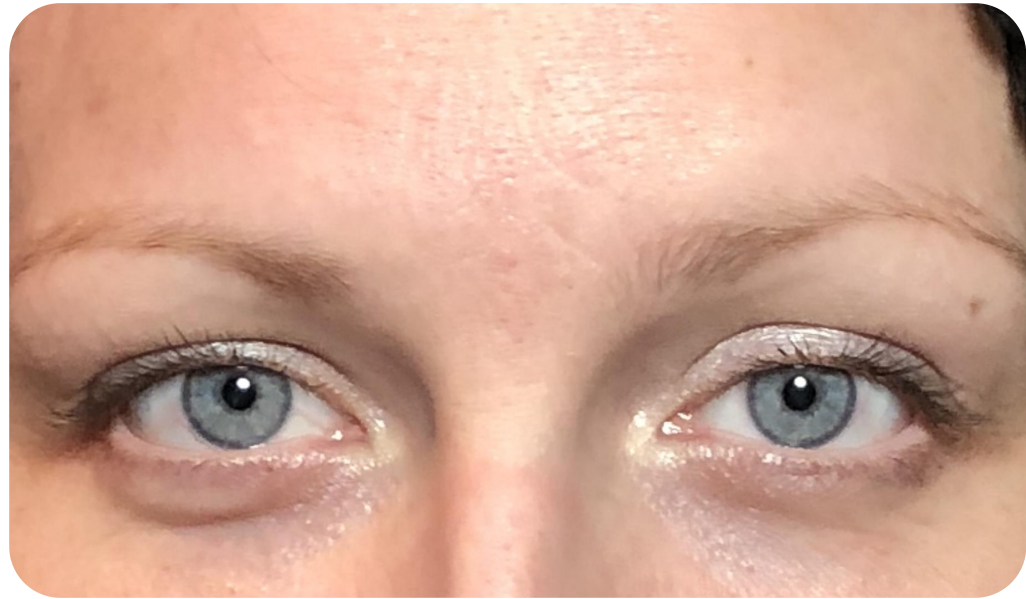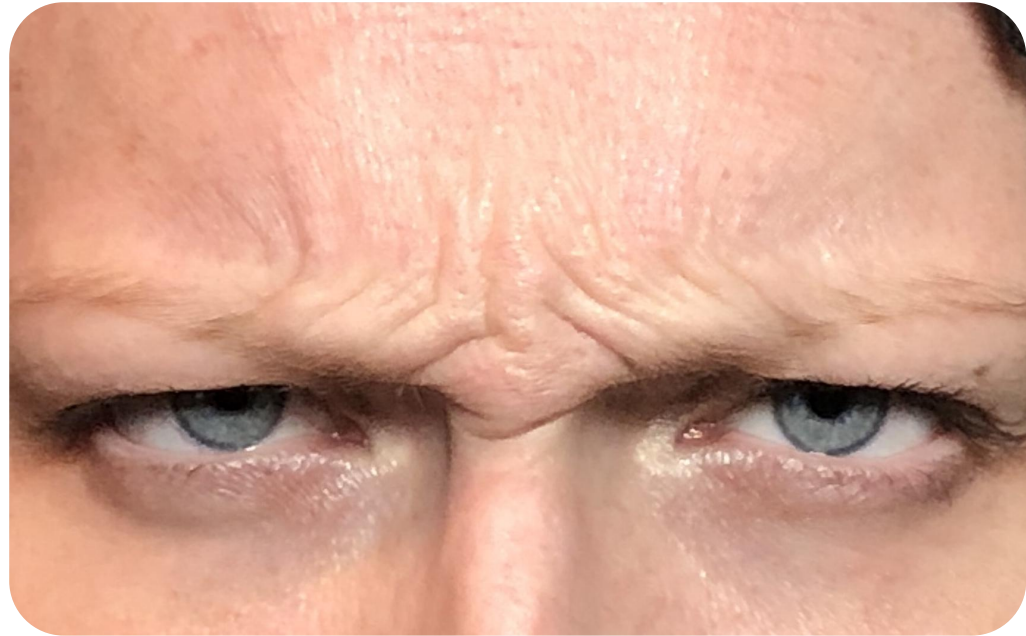
Botox

- Cosmetic benefits
 - Wrinkle reduction
- Clinical benefits
 - Migraines
 - Blepharospasm
- Functional concerns
 - Loss of muscle function
 - Impaired lid closure/blinking





Schwarzburg D. Doctor performing Botox injection, Wikimedia Commons. <https://skinlyaesthetics.com/wp-content/uploads/2020/02/doctor-injecting-botox.jpg>.
<https://commons.wikimedia.org/w/index.php?curid=117783248CC0>. Published January 28, 2020. Accessed March 23, 2024.



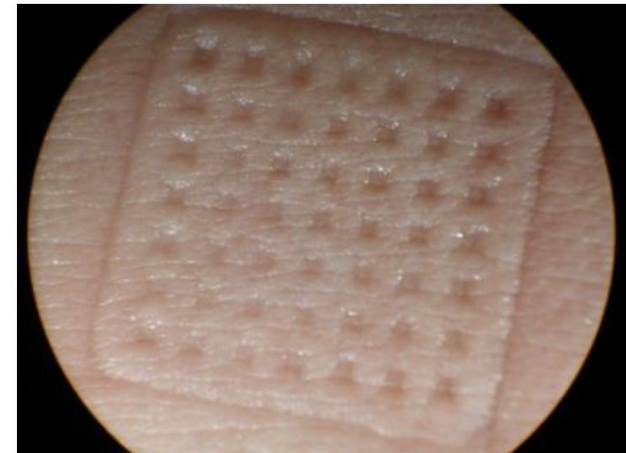



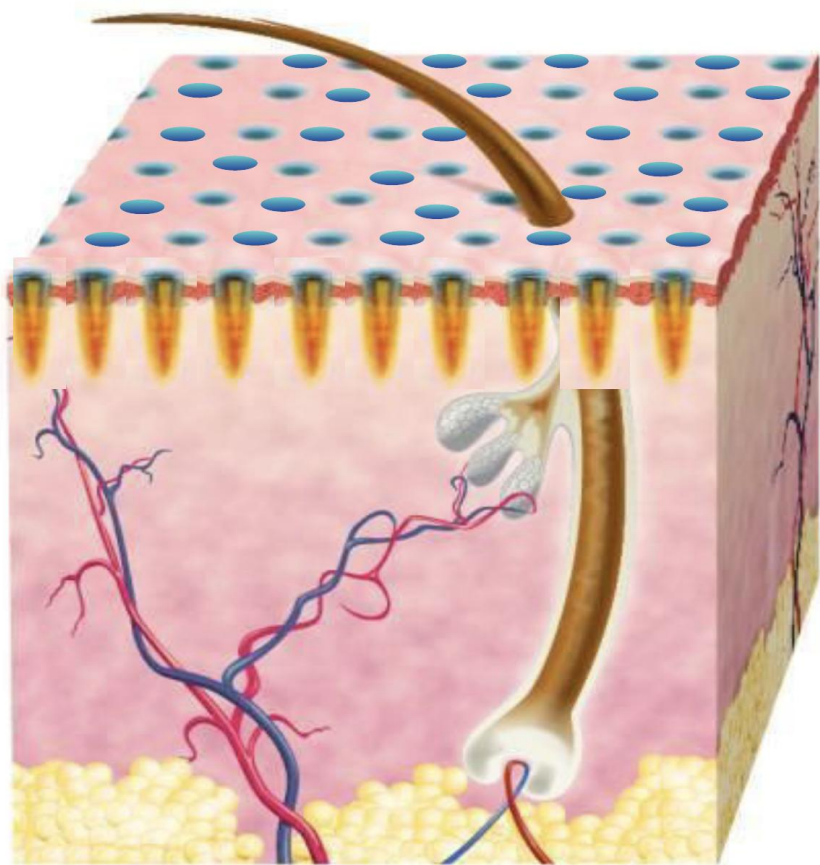
LASER RESURFACING

15mm, 320 mB/cm² &
XF Microlens 115mB/cm²

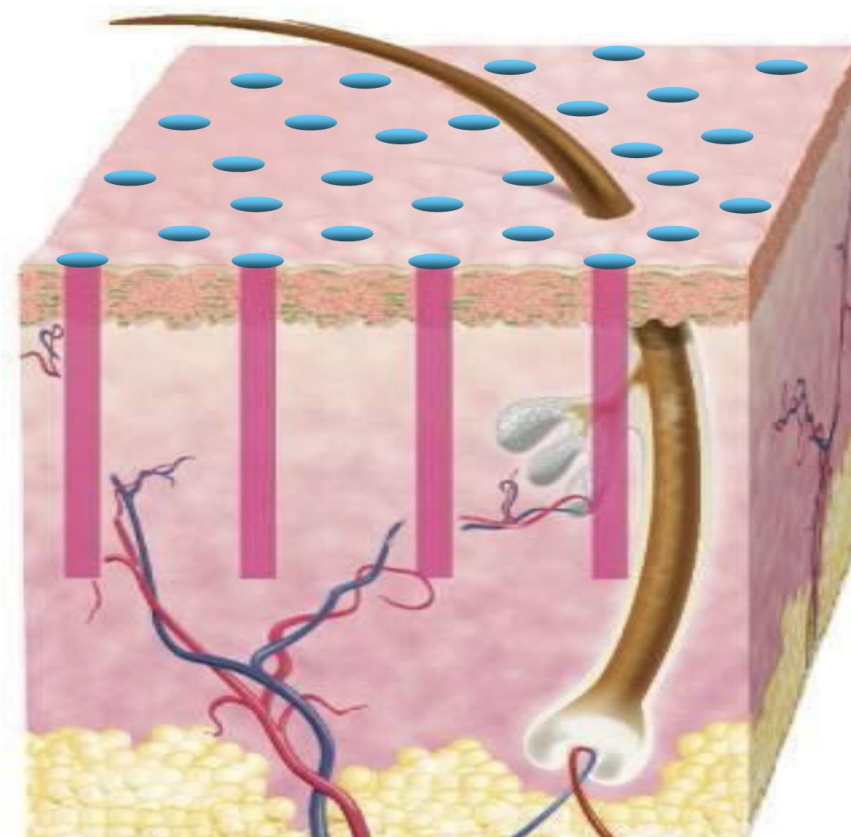


12mm x 12mm XD
25mB/cm²



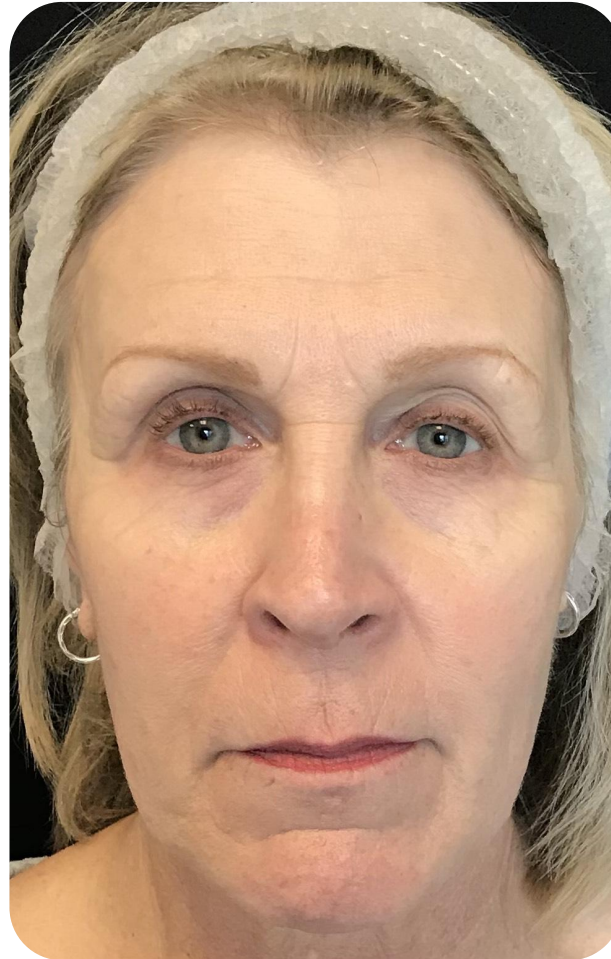
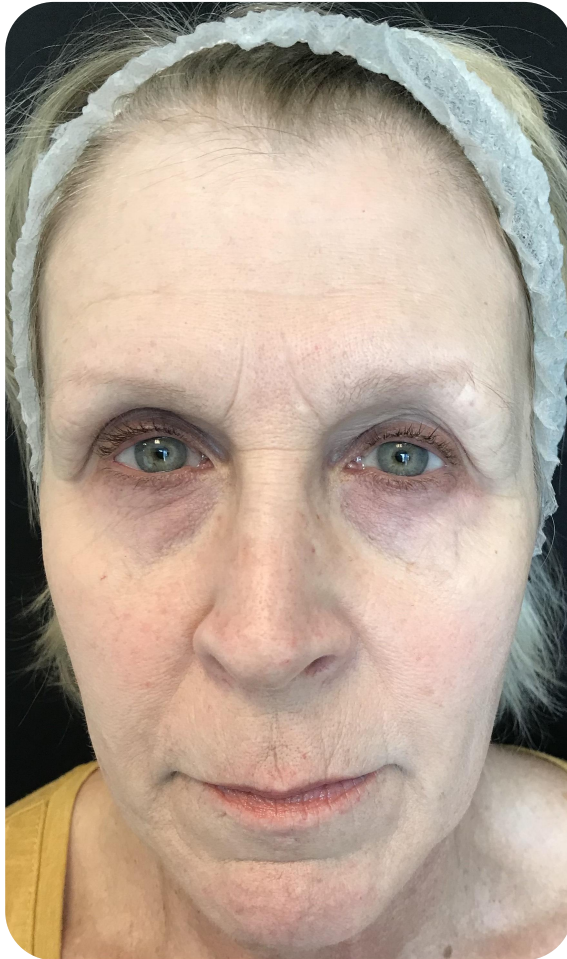
XF / 115mB/cm²



XD / 25mB/cm²

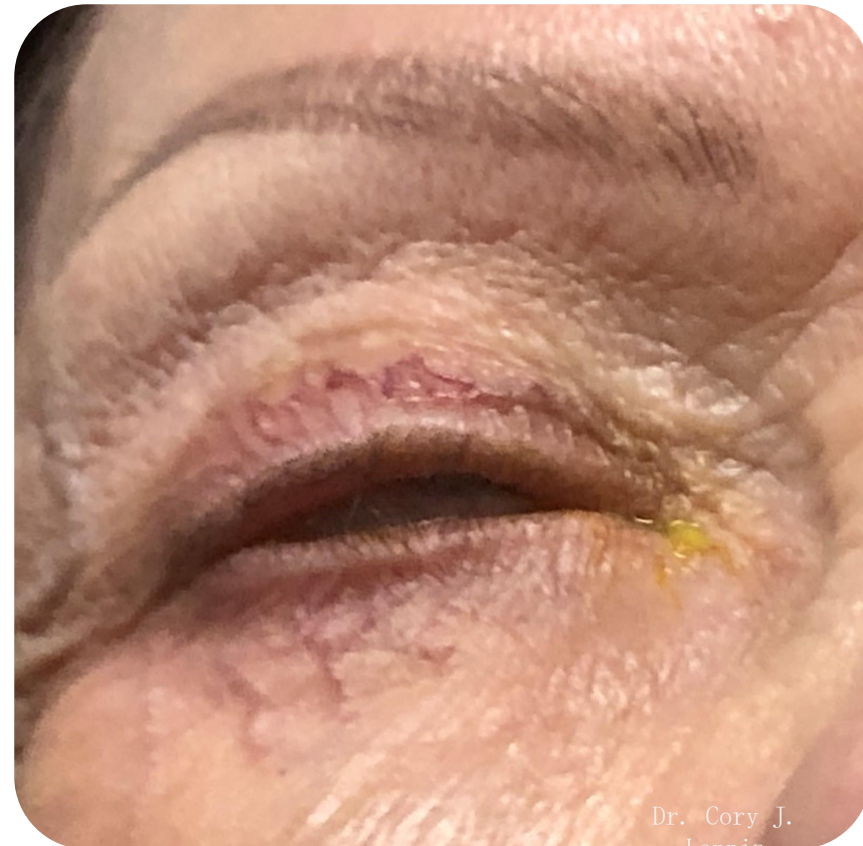IPL AND 1540 LASER




SURGICAL OPTIONS

Blepharoplasty

- **Cosmetic benefits**
 - Reduces “droopy/saggy” appearance
 - Removes “bags” under eyes
- **Functional benefits**
 - Improves field of vision
 - Improves exposure secondary to ectropion/entropion
- **Functional concerns**
 - Overcorrection
 - Lagophthalmos
 - Proper education and referral needed



Dr. Cory J.
Lippin



THANK YOU!

