



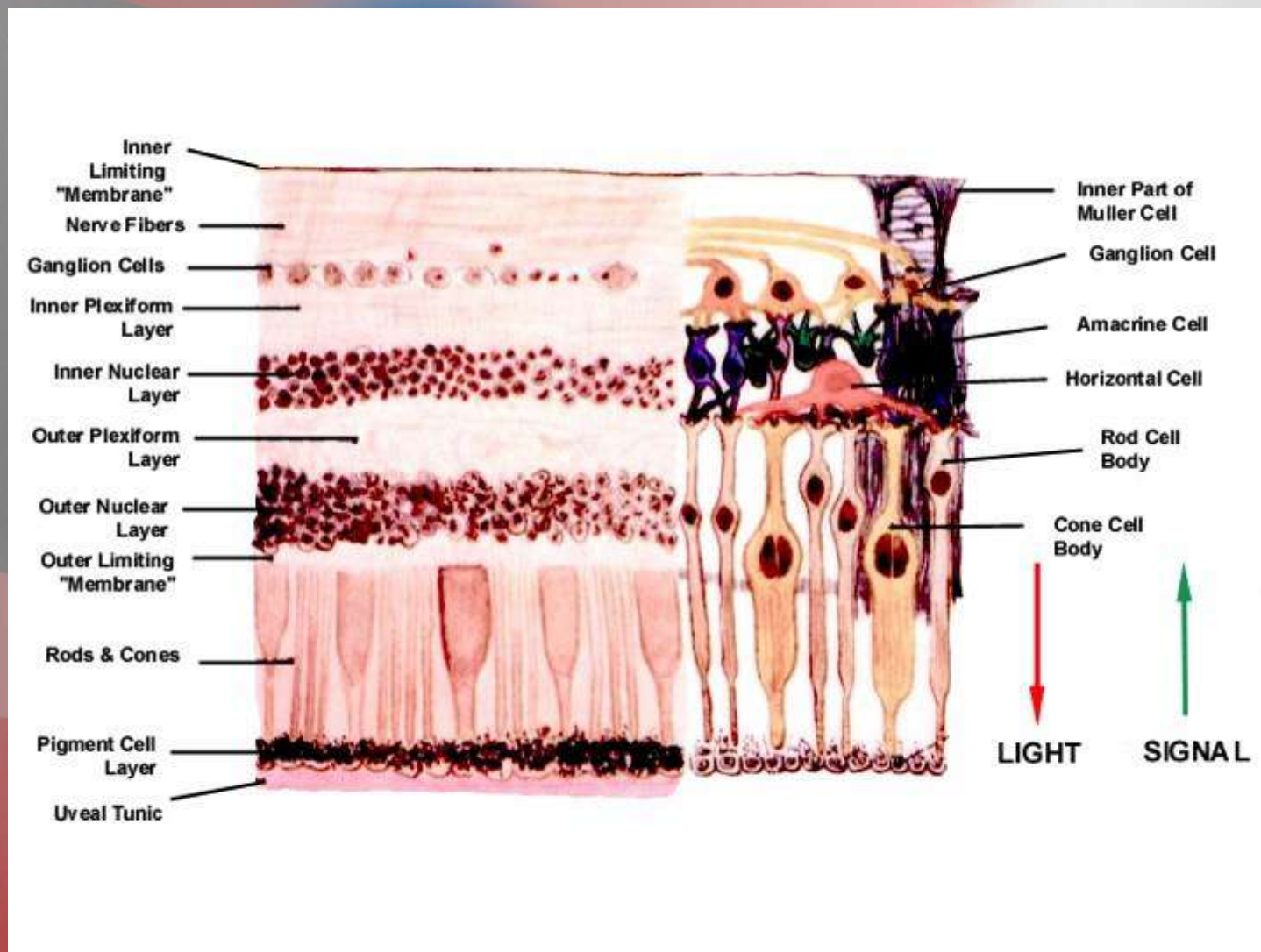
Getting Started With OCT

Julie Rodman OD, MSc, FAAO
Professor, Nova Southeastern University
College of Optometry

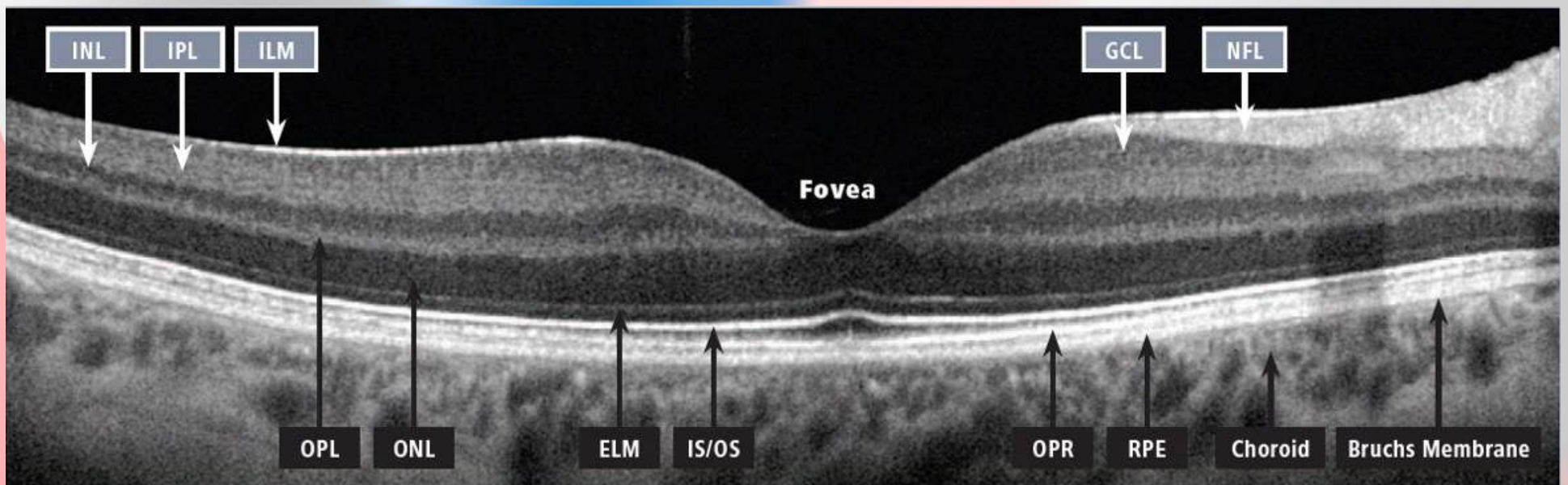


Disclosures:

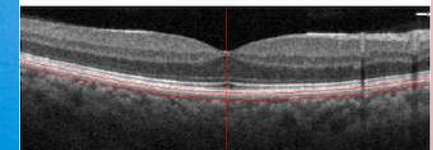
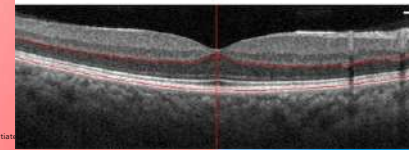
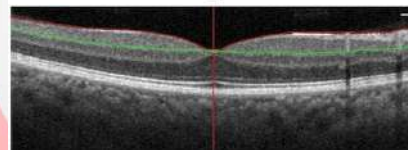
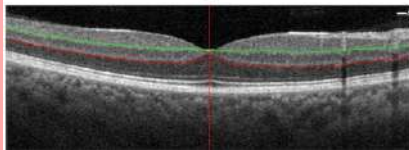
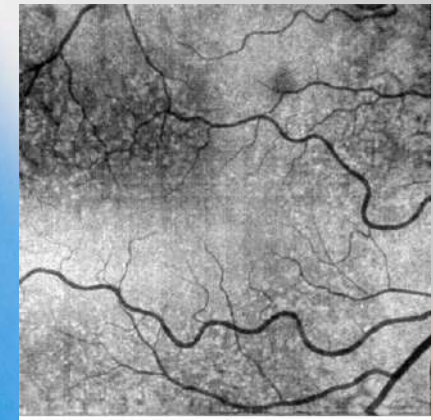
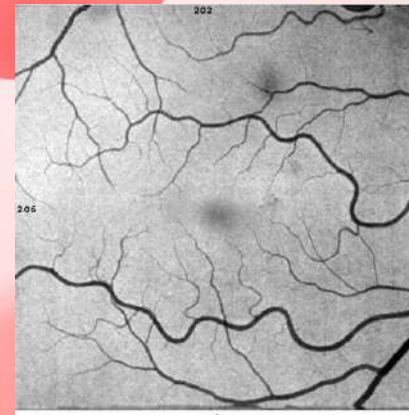
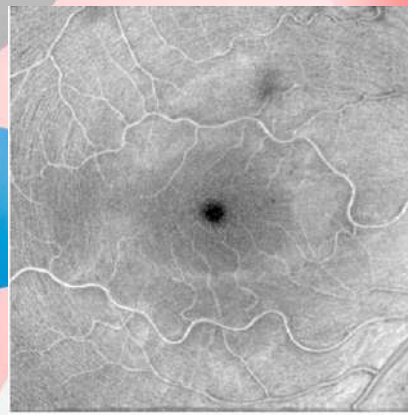
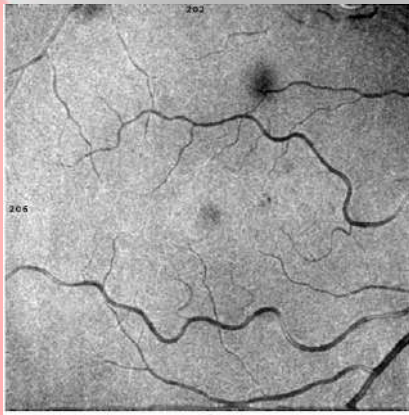
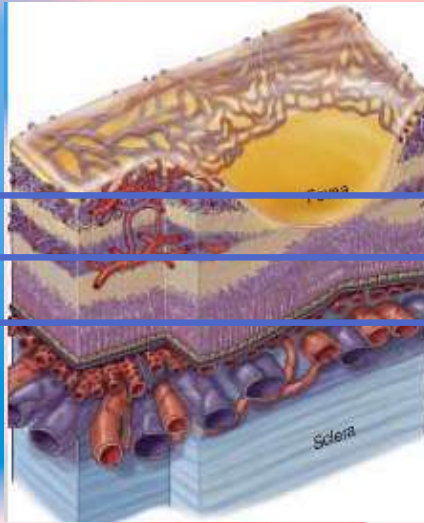
Speaker/Consultant: Optovue, iCare, Apellis



OCT B-Scan Layers



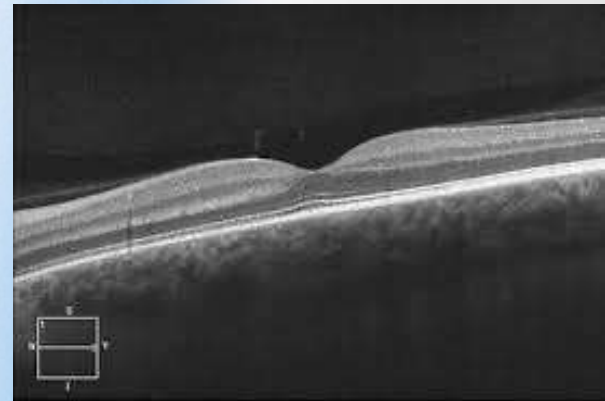
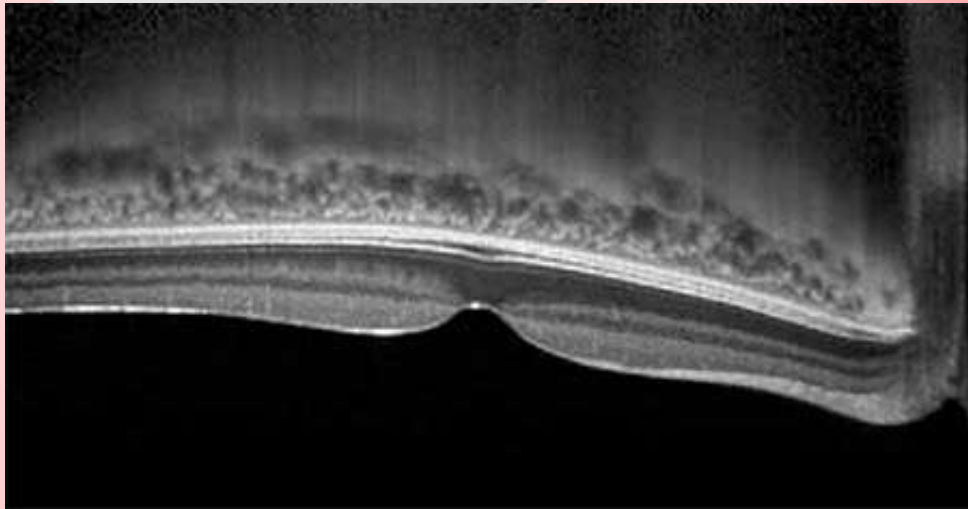
En Face Structural Visualization of Layers Based on Retinal Anatomy



Enhanced Depth Imaging

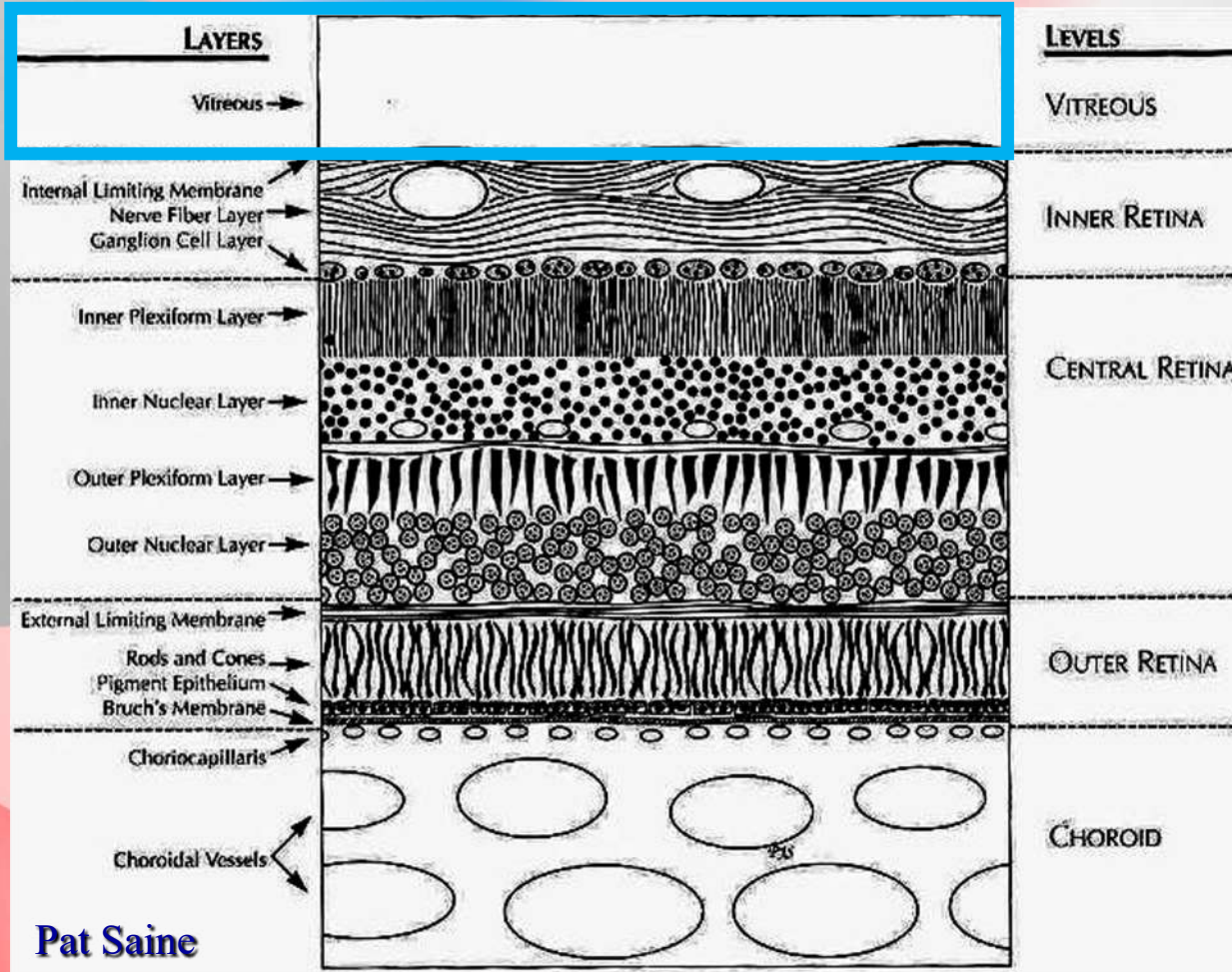
Place OCT closer to patient's eye; improves image resolution

Inverting the image provides enhanced visualization of the RPE, Bruch's membrane, choroid and sclera (extra 500-800 um penetration)



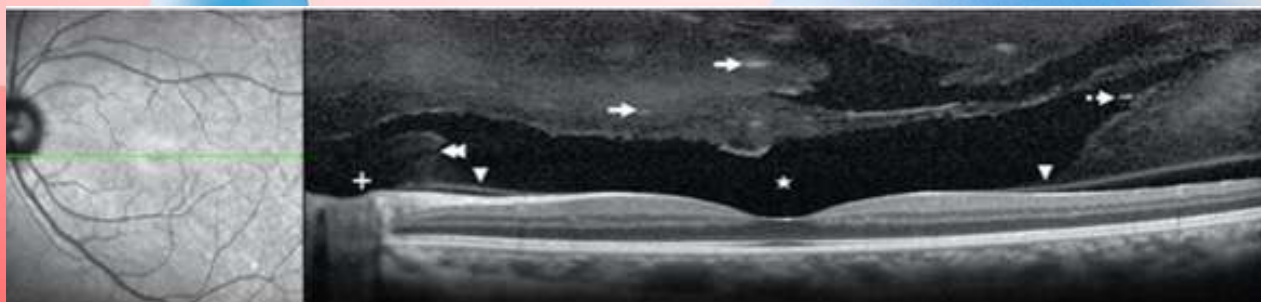
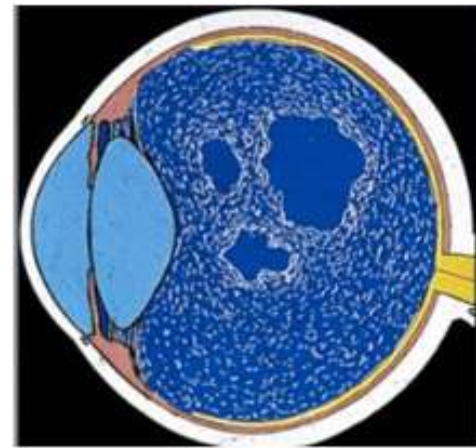
The background features a light pink gradient with several overlapping circles in shades of blue, red, and white. A dashed teal line is positioned on the left side, curving around a large white circle. The text 'Anomalies of the Vitreous' is centered in a black, sans-serif font.

Anomalies of the Vitreous



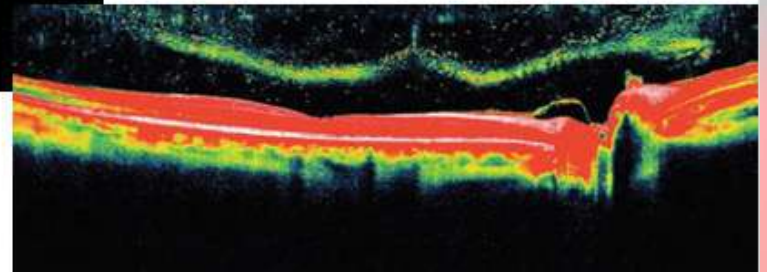
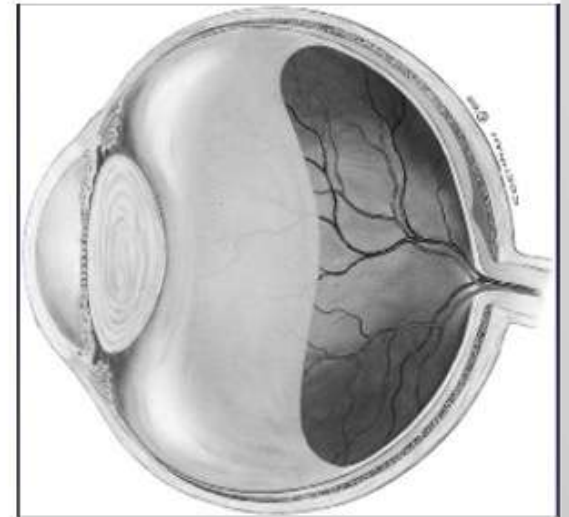
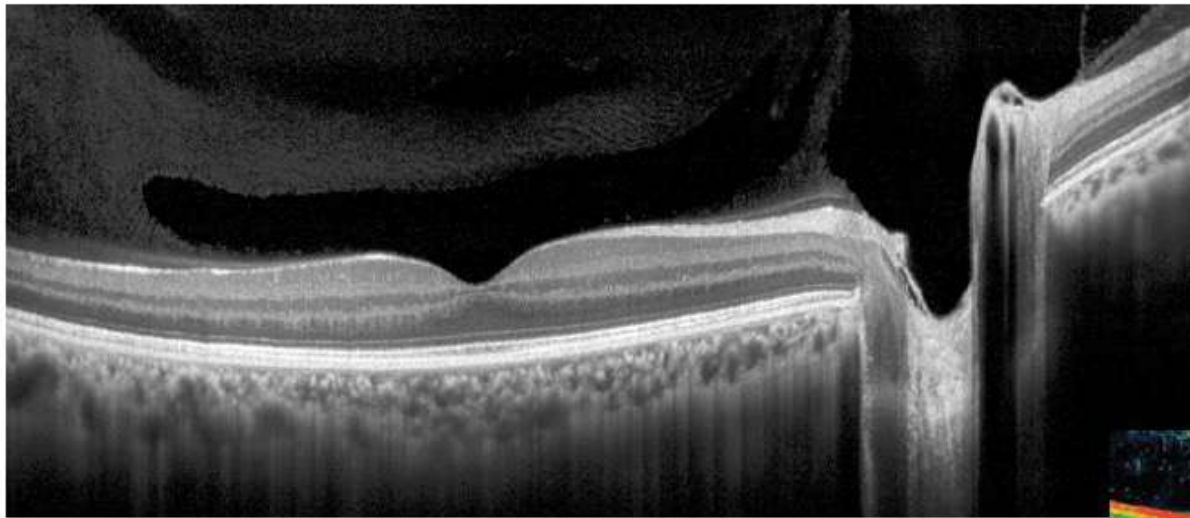
Aging of the Vitreous: Two Processes

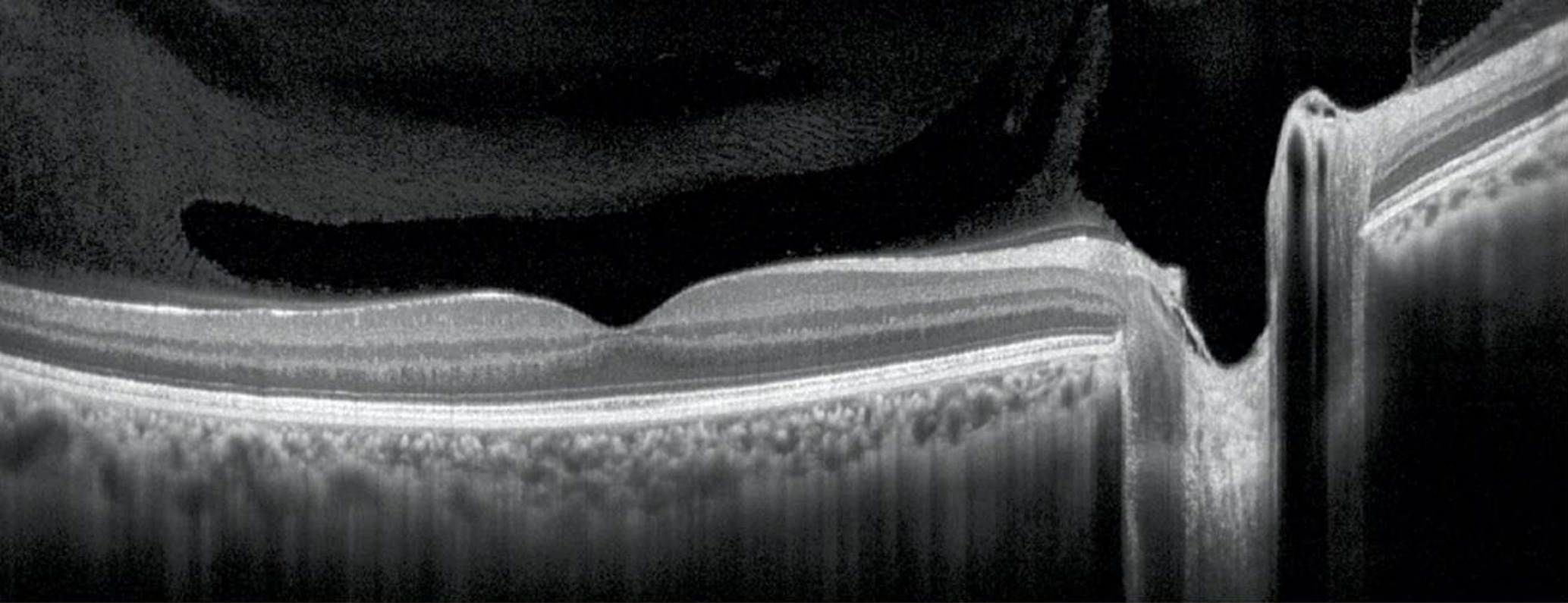
Synchysis (liquefaction of the vitreous gel)



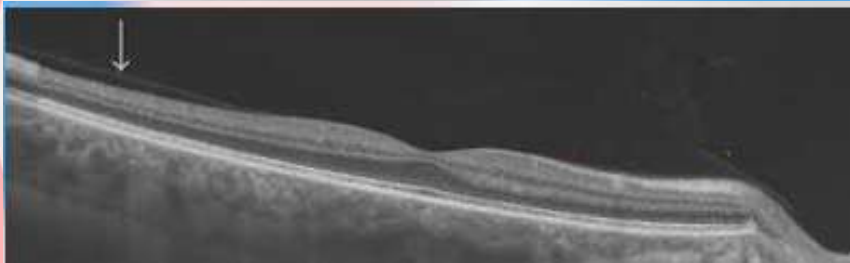
Aging of the Vitreous: Two Processes

Syneresis (Contraction of the Vitreous Gel)

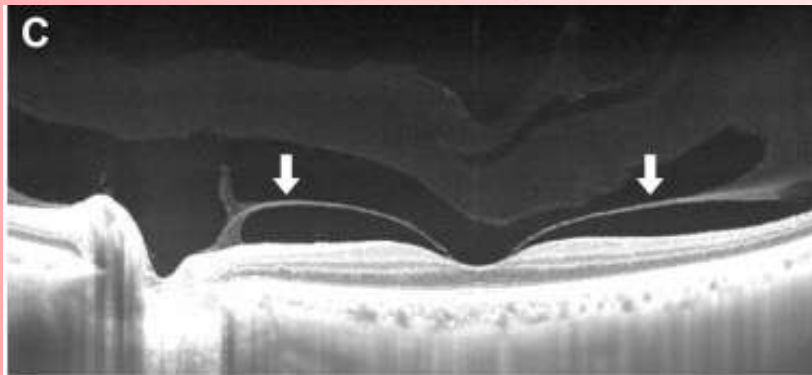




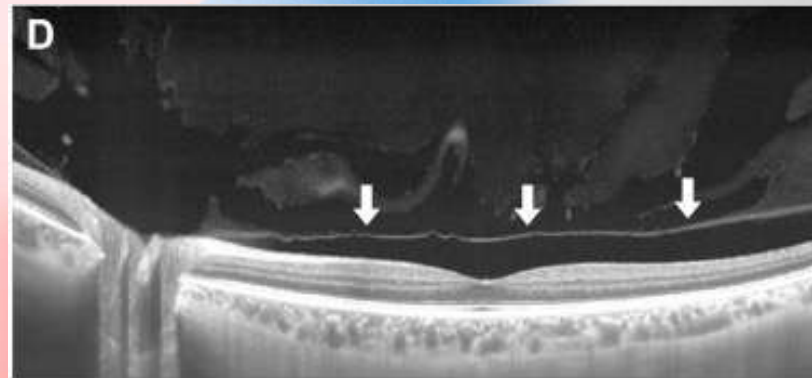
Stages of PVD




Stage 1: Single quadrant of perifoveal detachment



Stage 2: 360 degrees perifoveal detachment

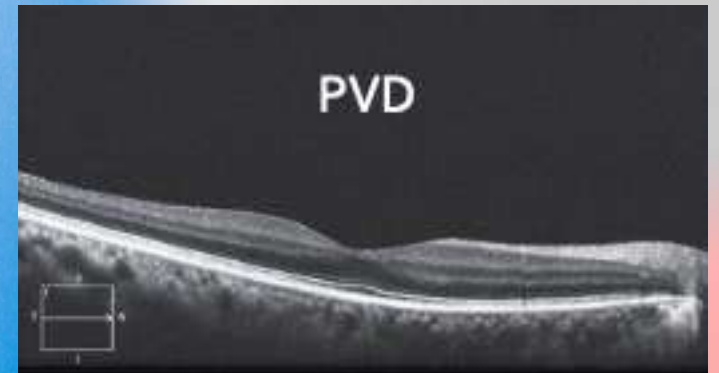
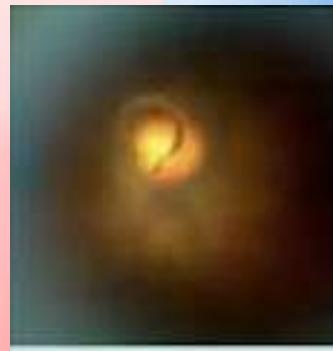
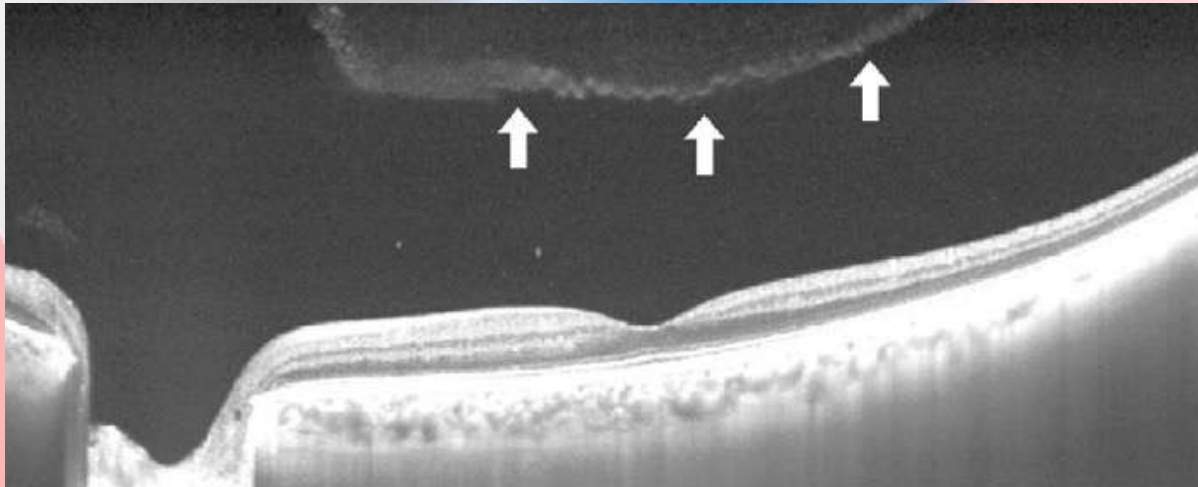


Stage 3: Vitreofoveal separation with adhesion at ONH

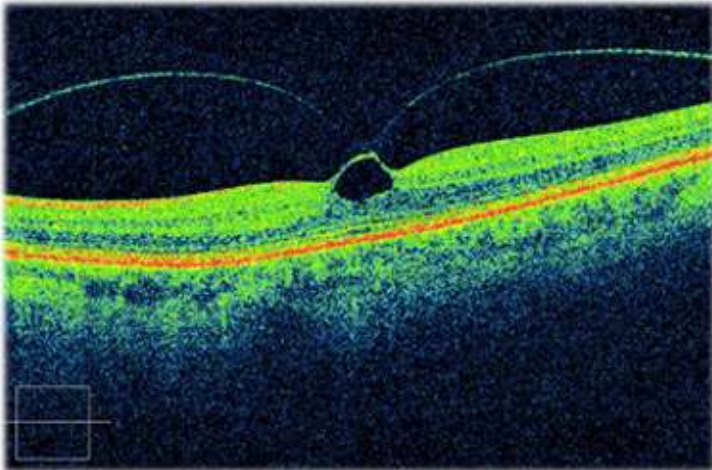


Vitreous behavior in a high myope

Posterior Vitreous Detachment

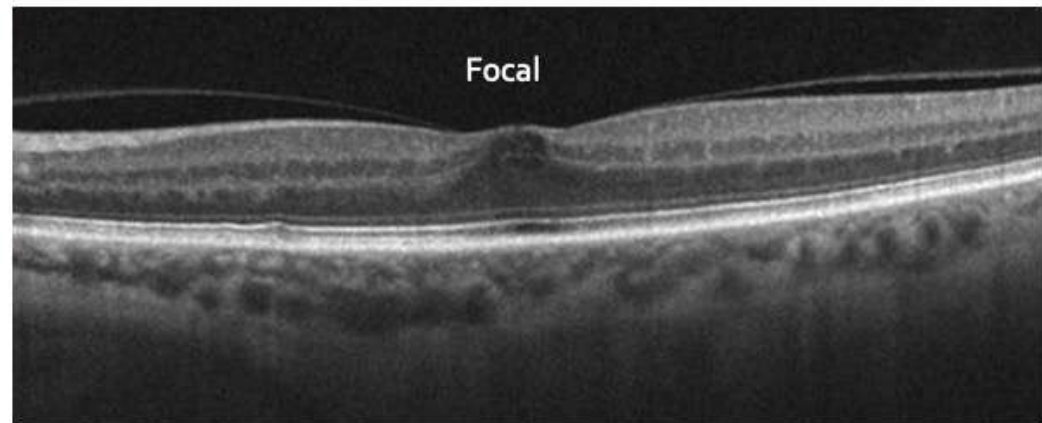
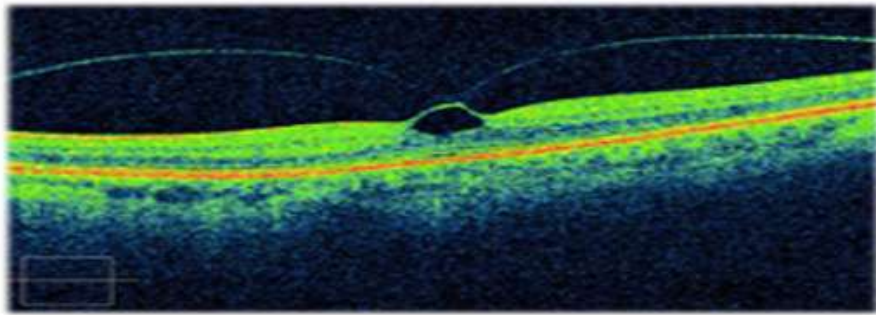


Vitreomacular Traction

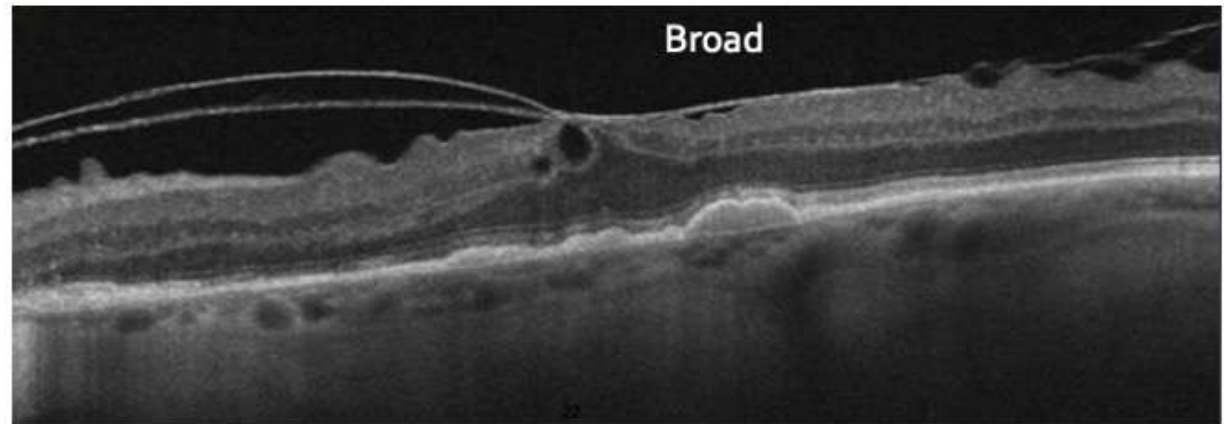
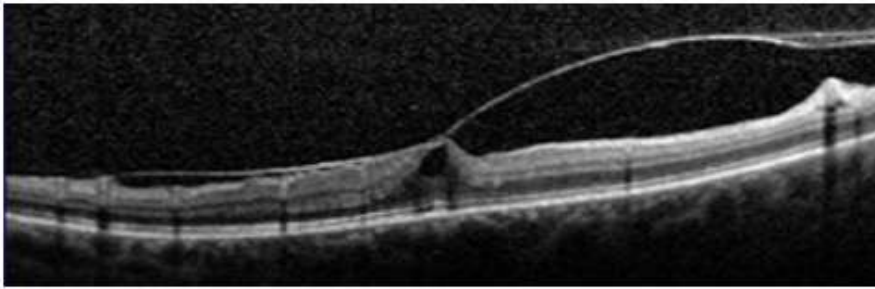


Attachment of the vitreous cortex to the macula within a 3 mm radius of the fovea resulting in distortion of the foveal surface

Focal VMT: <1500 μm

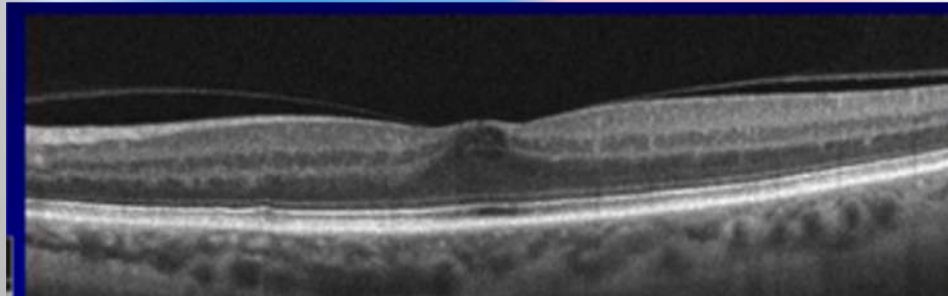


Broad VMT: >1500 μm

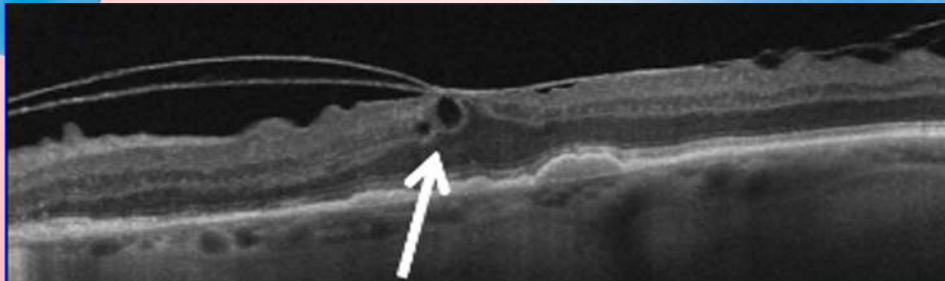


Isolated versus Concurrent

Isolated

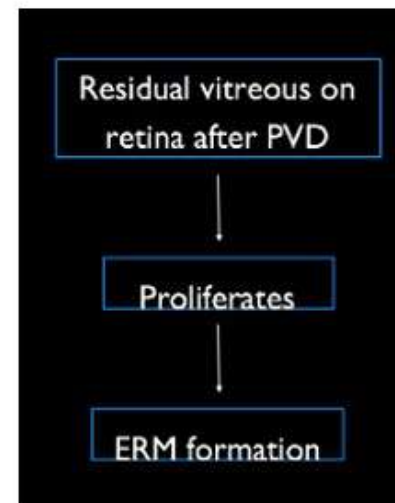
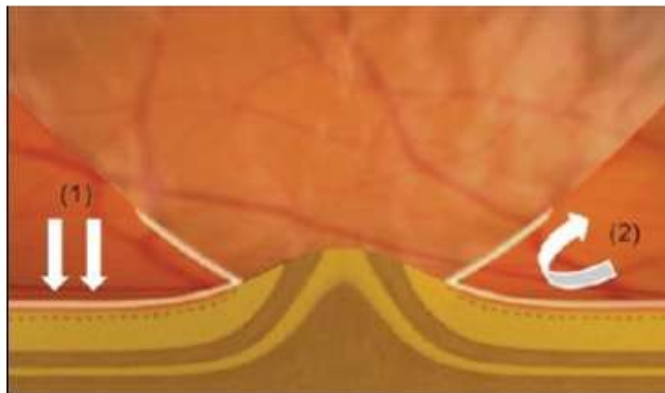


Concurrent

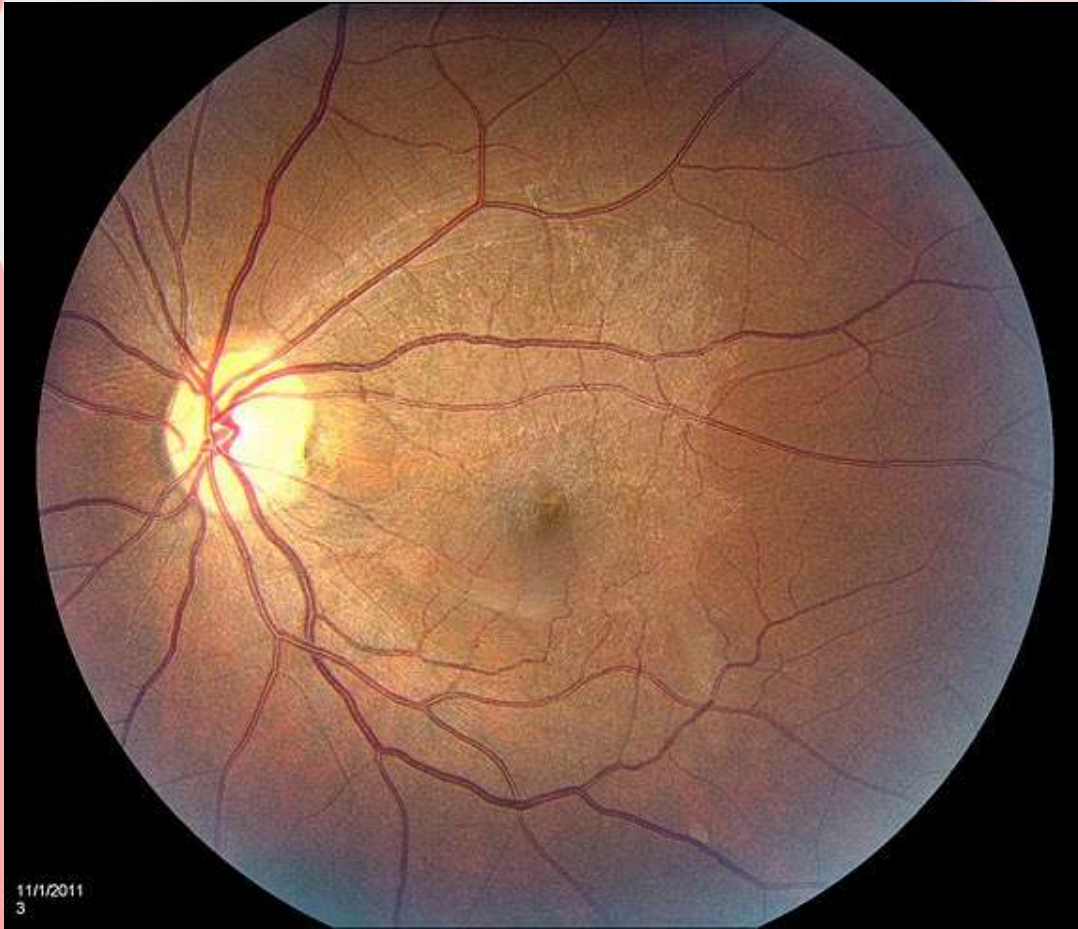


With PVD progression, residual vitreous tissue is left on inner retinal surface...

Residual vitreous proliferates to form ERM

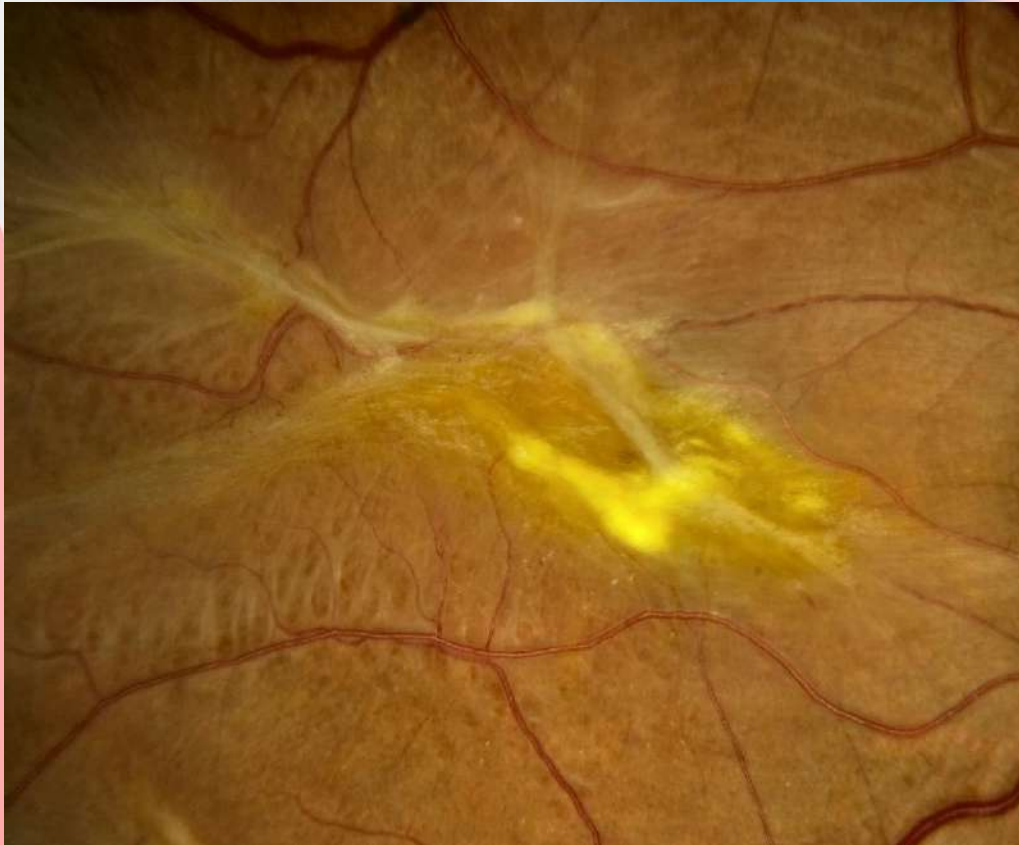

Epiretinal membrane: Grade 1

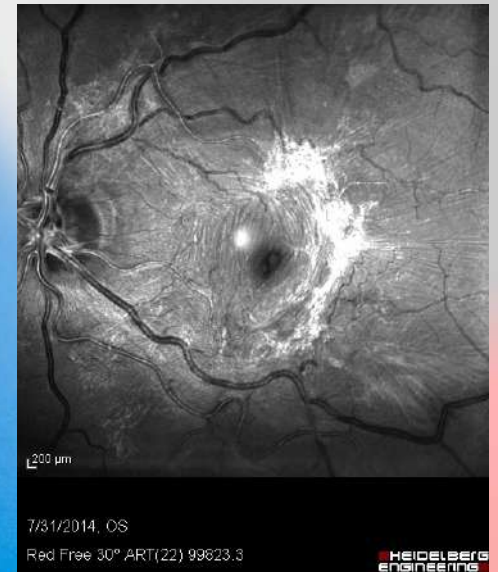

A cellophane-like sheen is observed over the macular area, causing very *mild wrinkling* of the inner retinal surface, with *little or no modification of retinal vessel trajectory*. These membranes are rarely symptomatic.

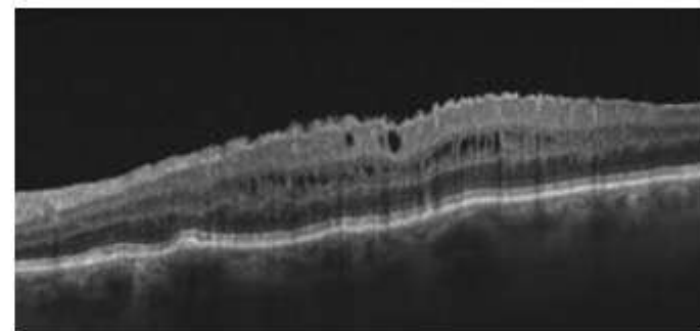
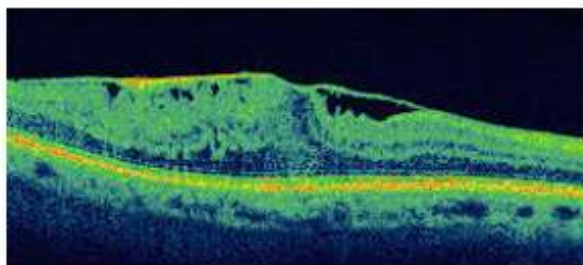
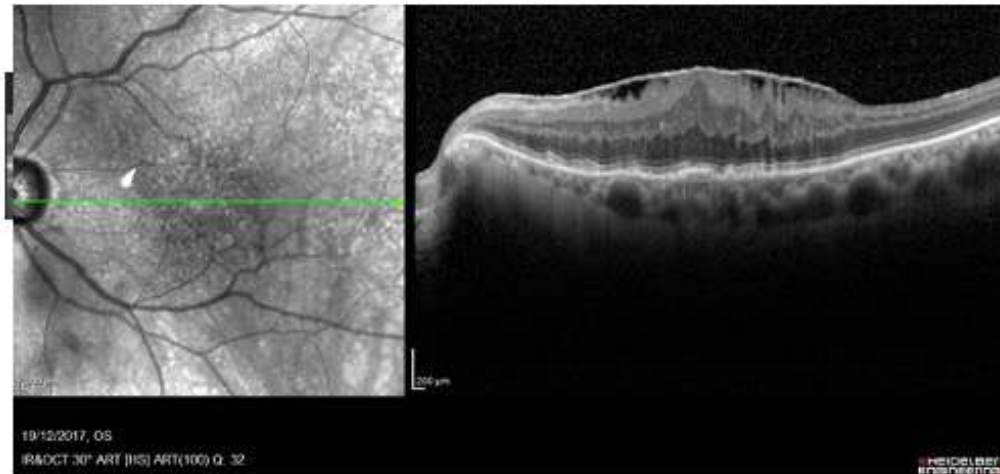
Epiretinal membrane: Grade 2


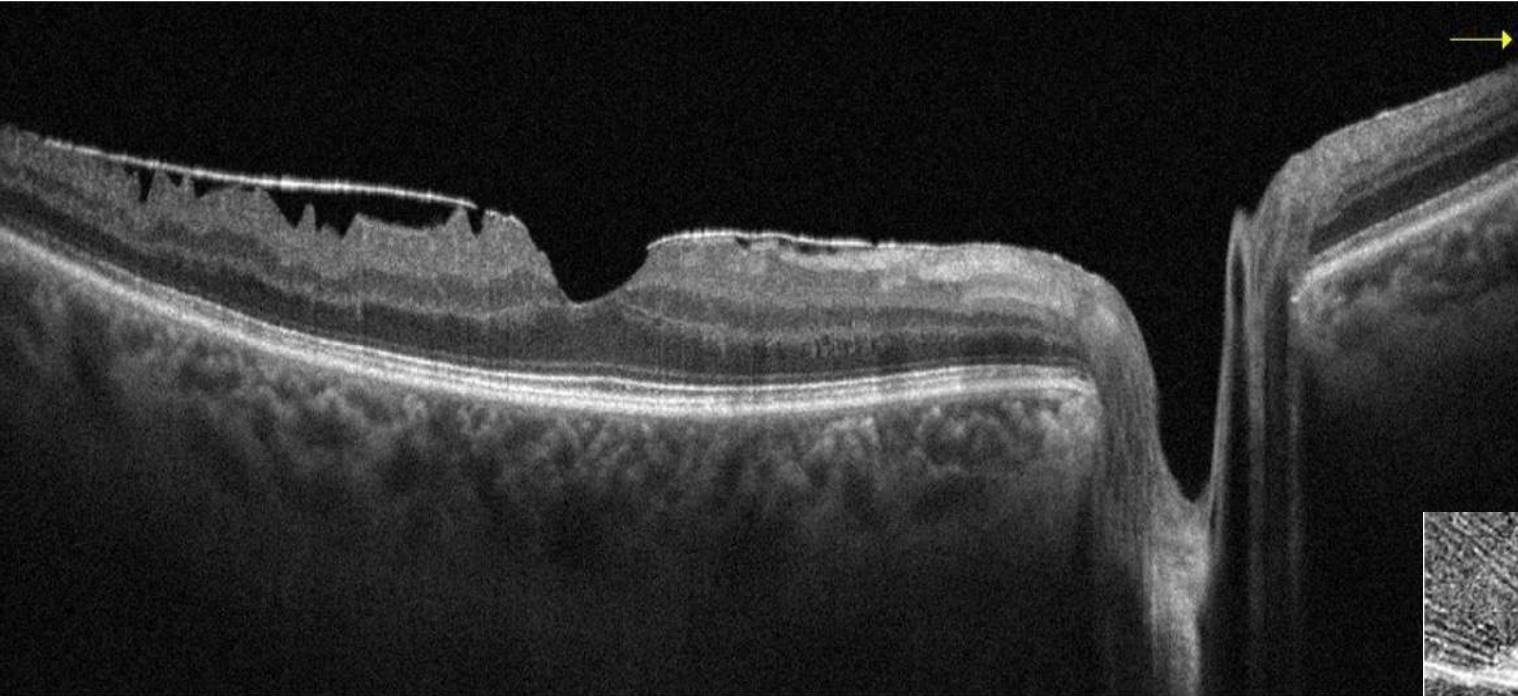


Fibrous tissue is observed over the macular area, causing significant wrinkling of the retinal surface and modification of the retinal vessel trajectory.

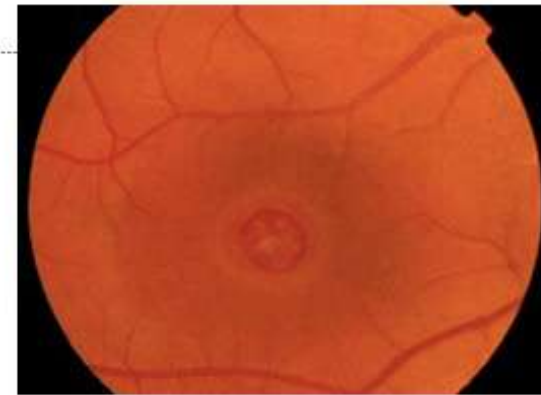
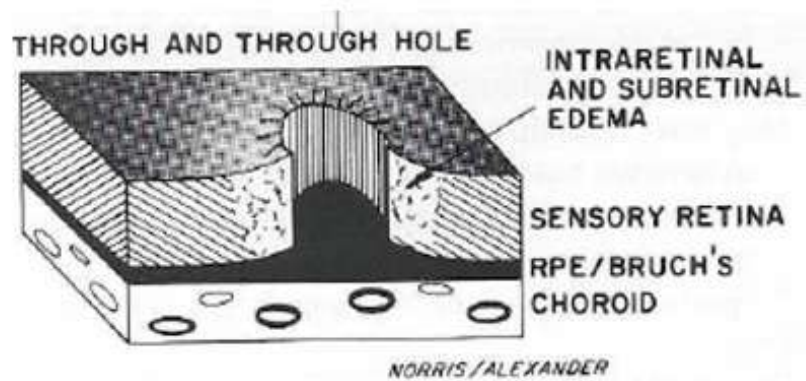


Epiretinal Membrane: OCT

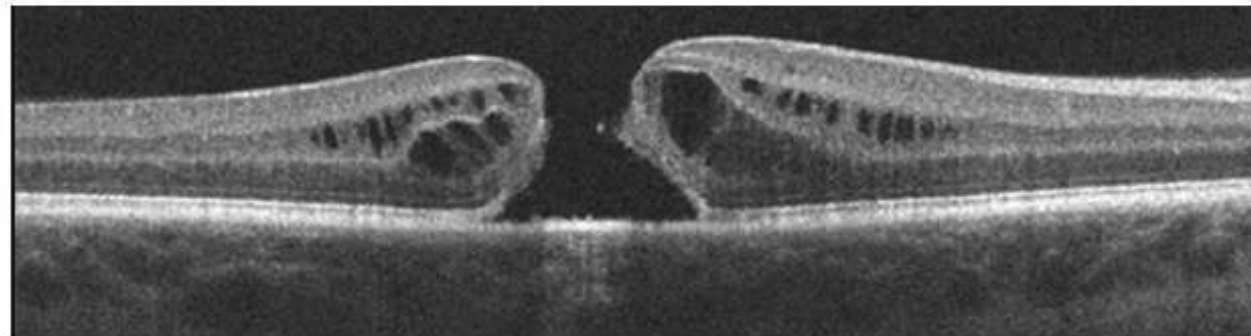




Full Thickness Macular Hole



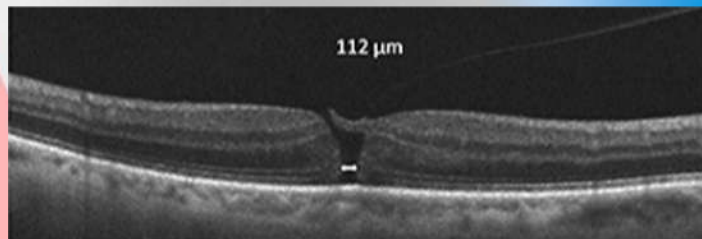
Defect spans entire width of neurosensory retina



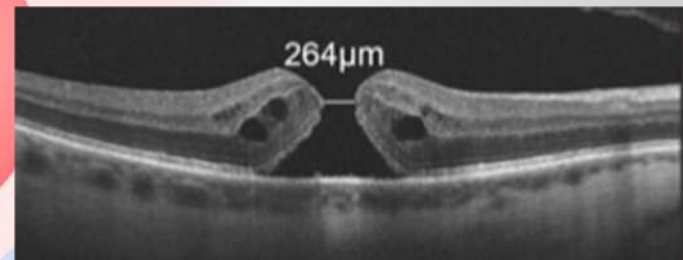
Small: Full thickness defect; ≤ 250 μm

Medium: Full thickness defect; >250 μm and ≤ 400 μm

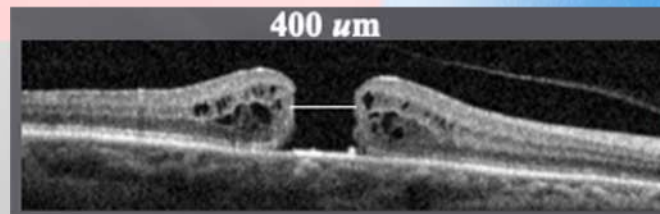
Large: Full thickness defect; >400 μm



Small

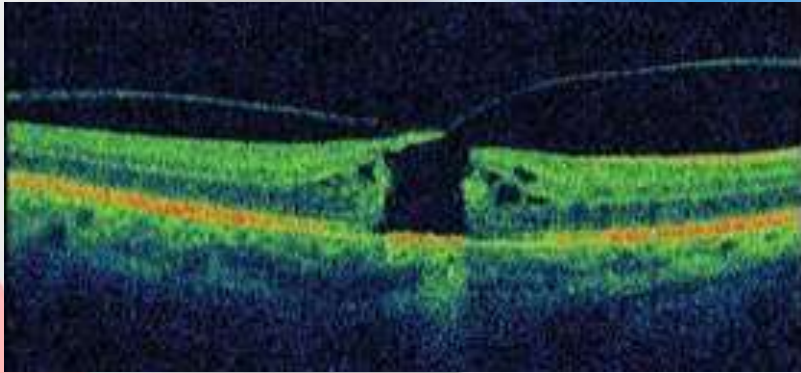


Medium

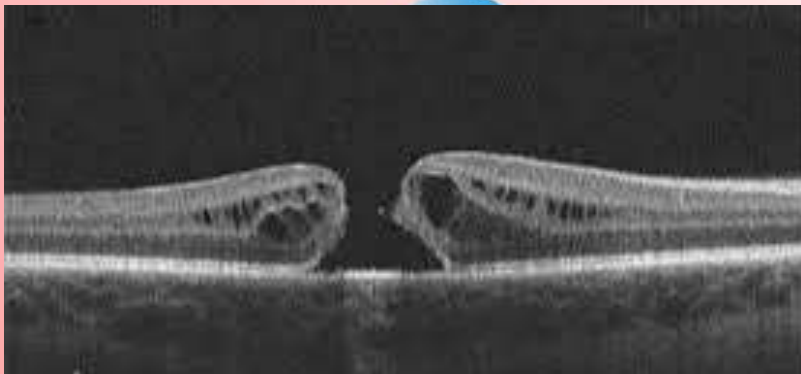

Large

Is there VMT?? Primary versus Secondary

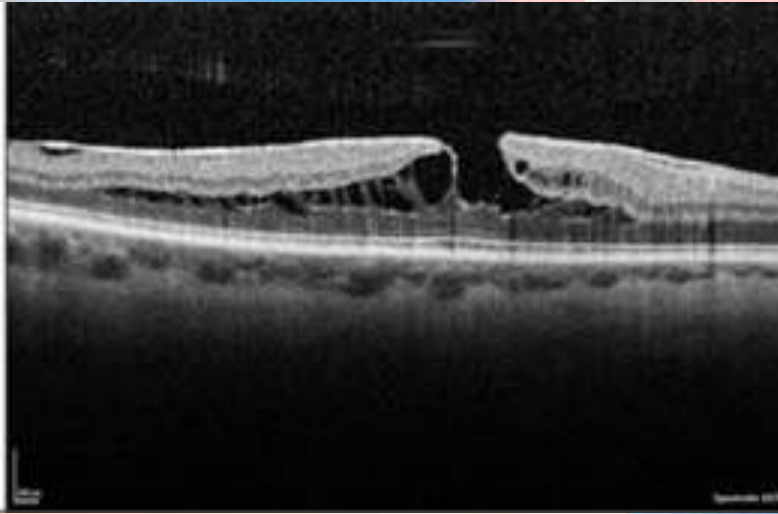


Primary



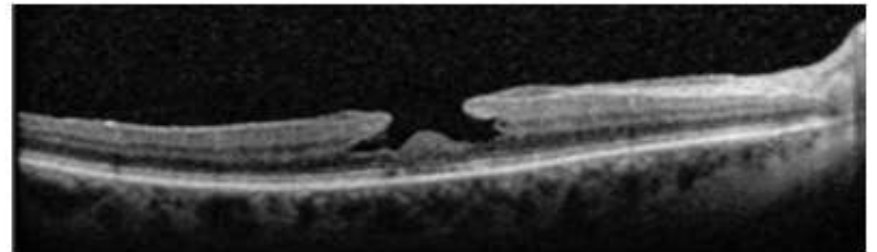
Secondary

Partial Thickness Macular Hole: Lamellar

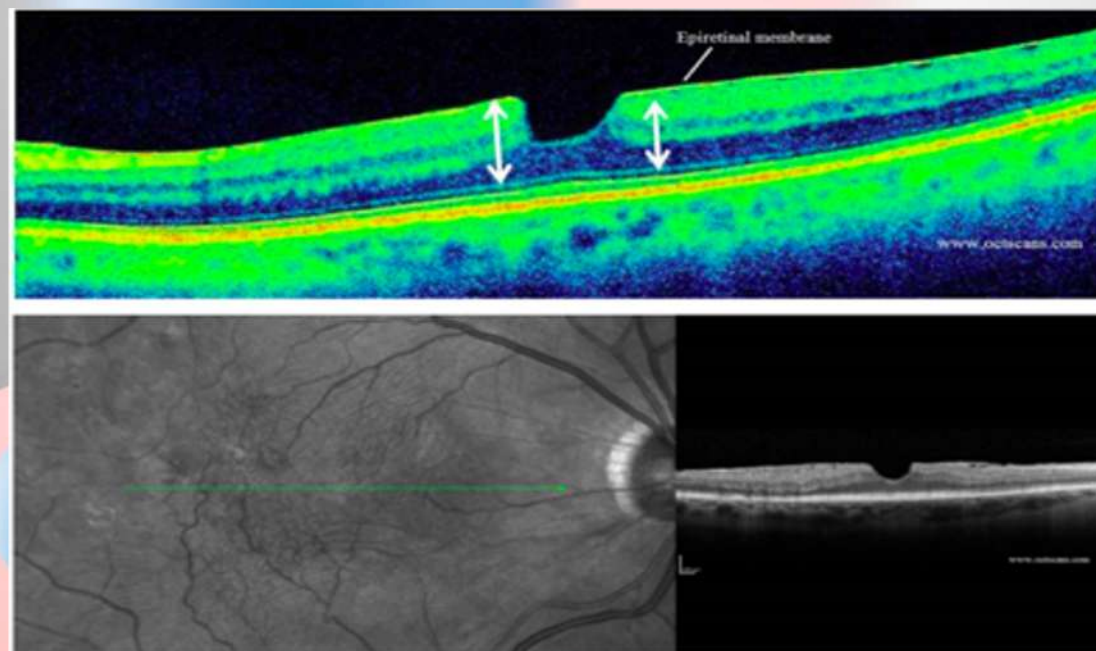


Tractional:
Epiretinal membrane
Foveal schisis

Degenerative:
Epiretinal proliferation
Round edges
Incomplete break

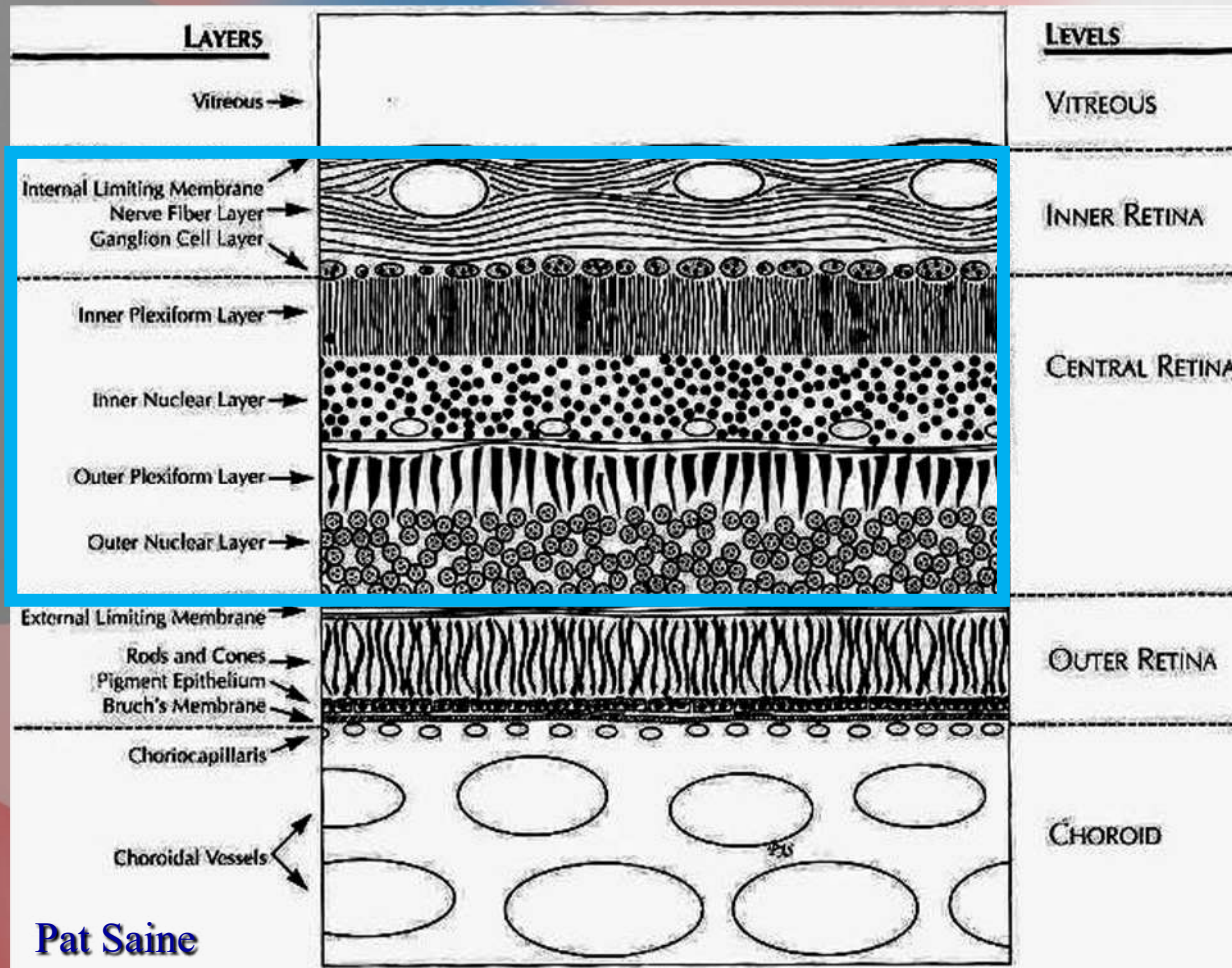


Partial Thickness Macular Hole: Pseudohole





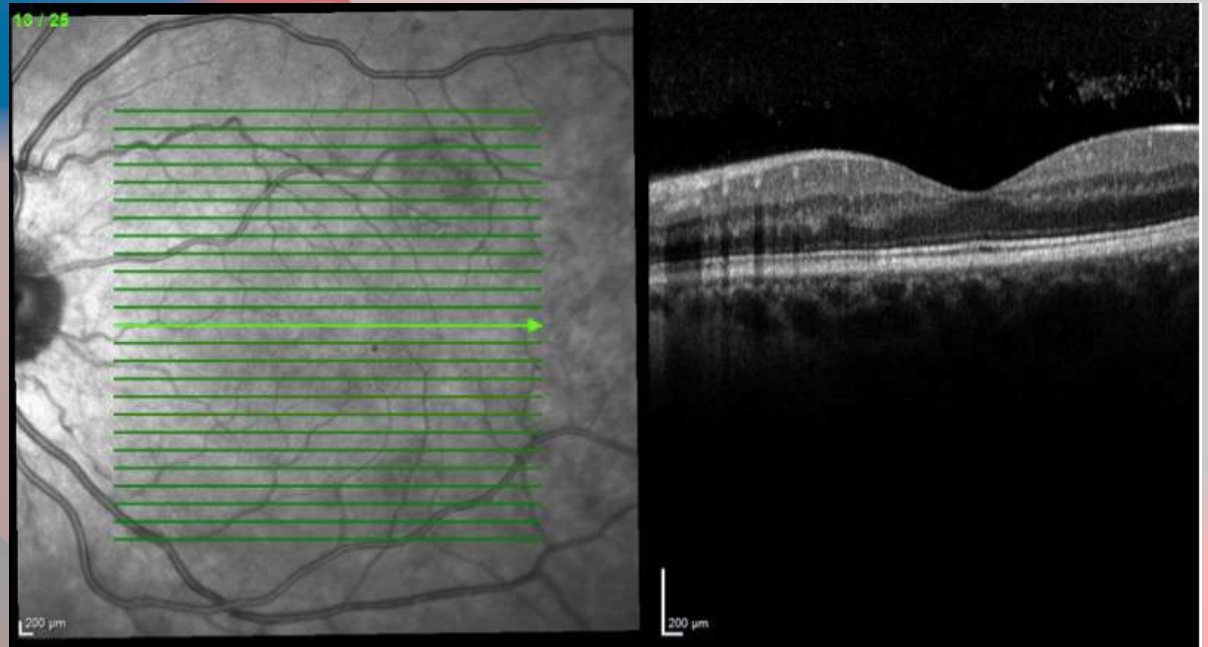
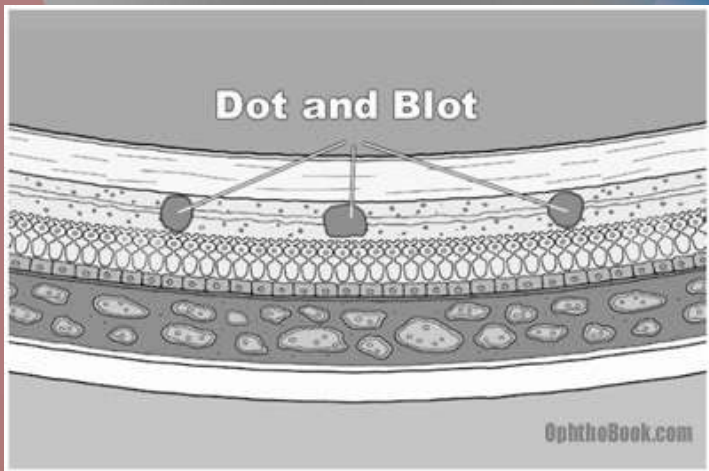
Inner Retinal Disease



Diabetic Retinopathy: Non-Proliferative

Hemorrhage: HYPER-reflective

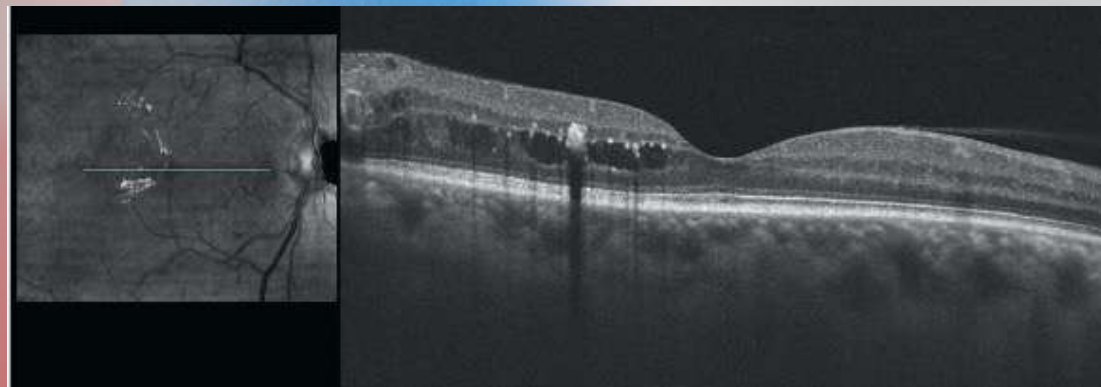
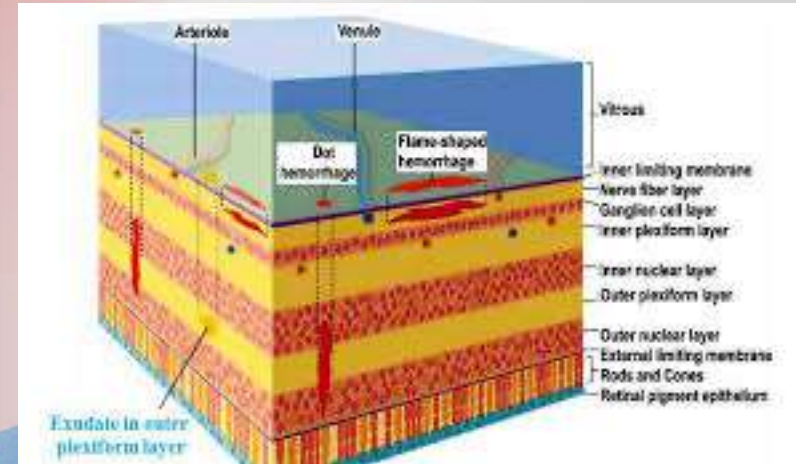
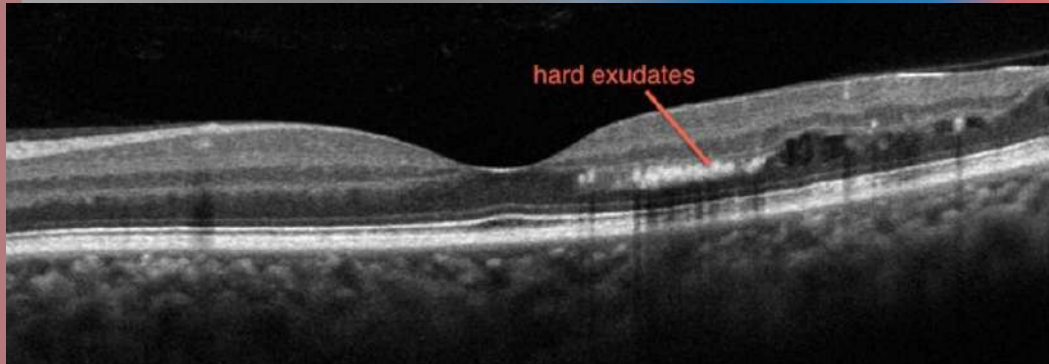
** Check the layer ***



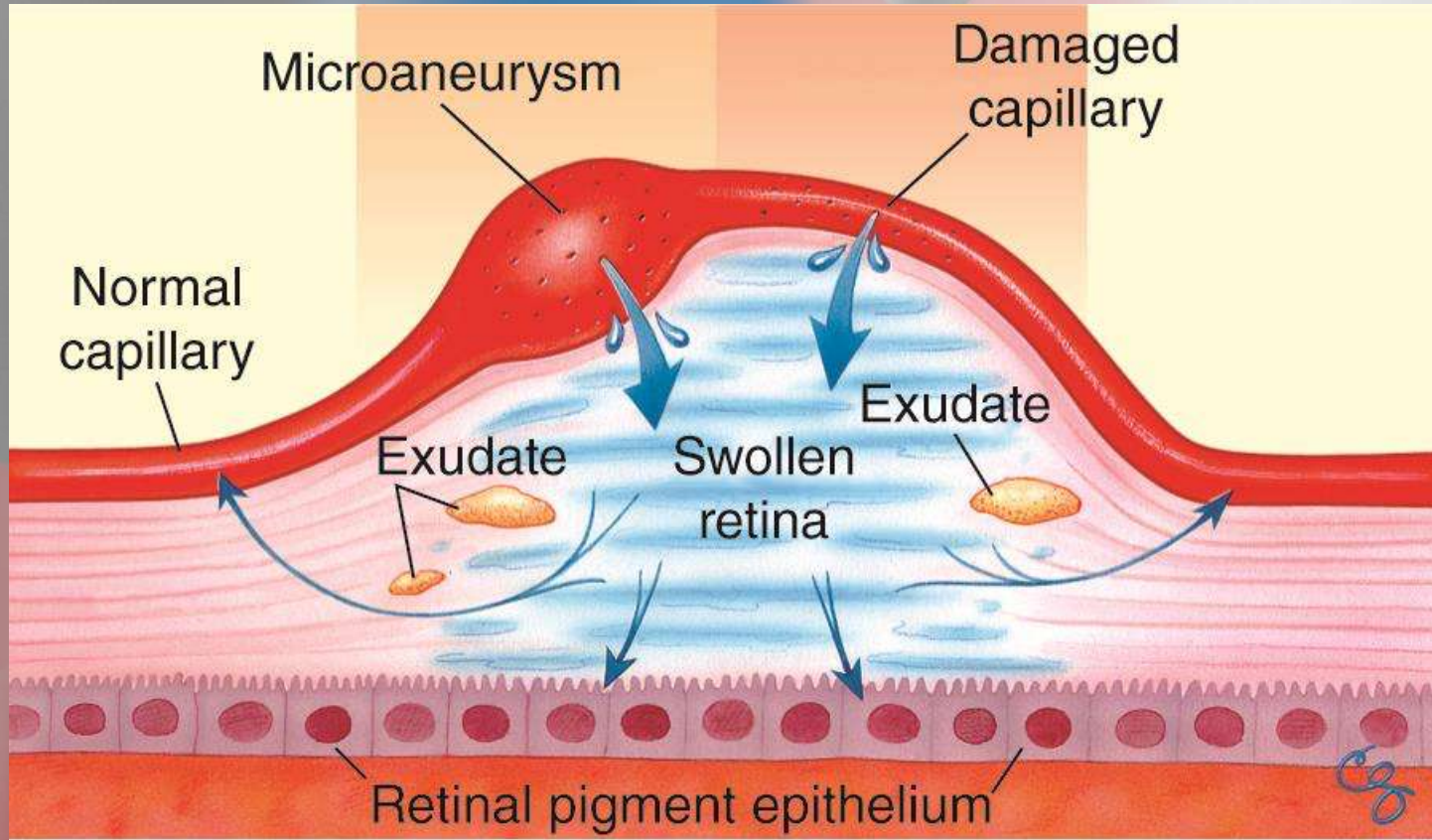
Diabetic Retinopathy: Non-Proliferative

Exudate: HYPER-reflective

** Check the layer ***

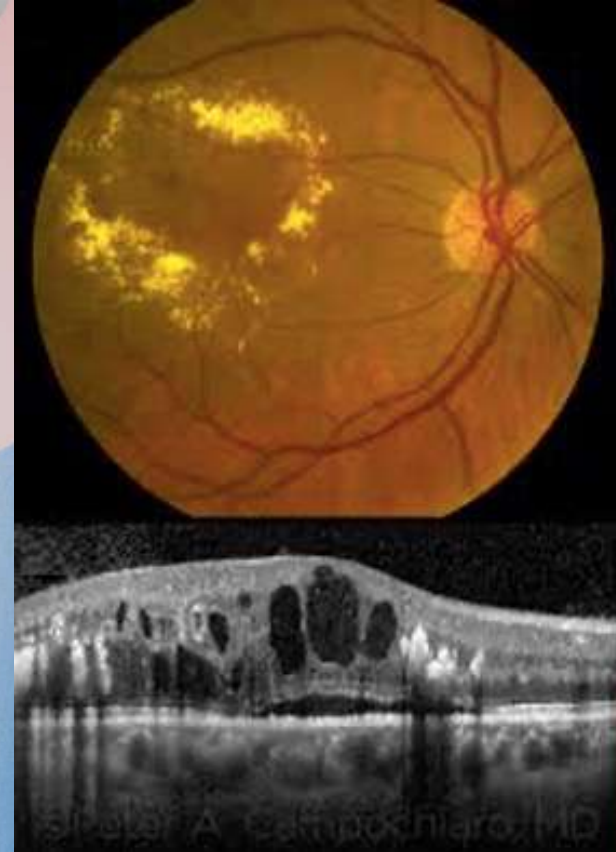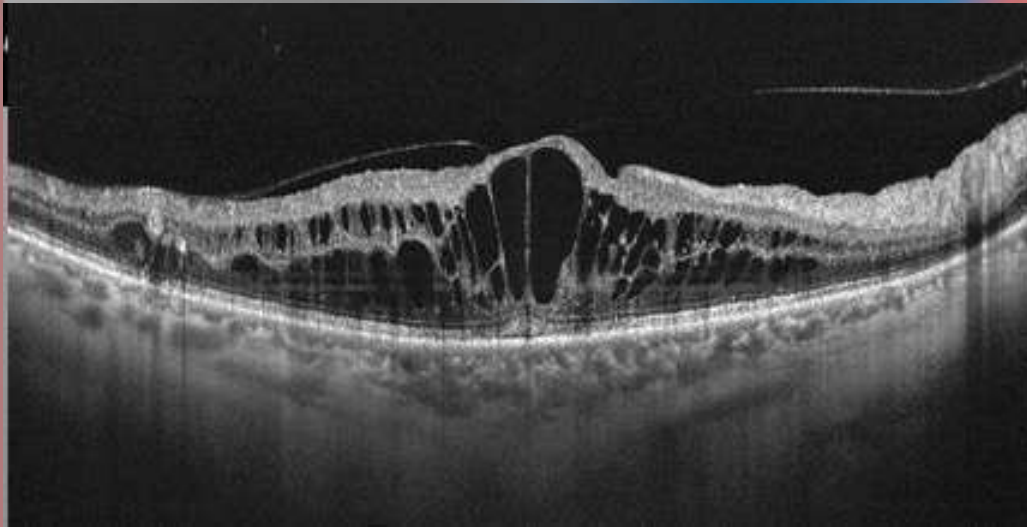


Diabetic Retinopathy: Macular Edema


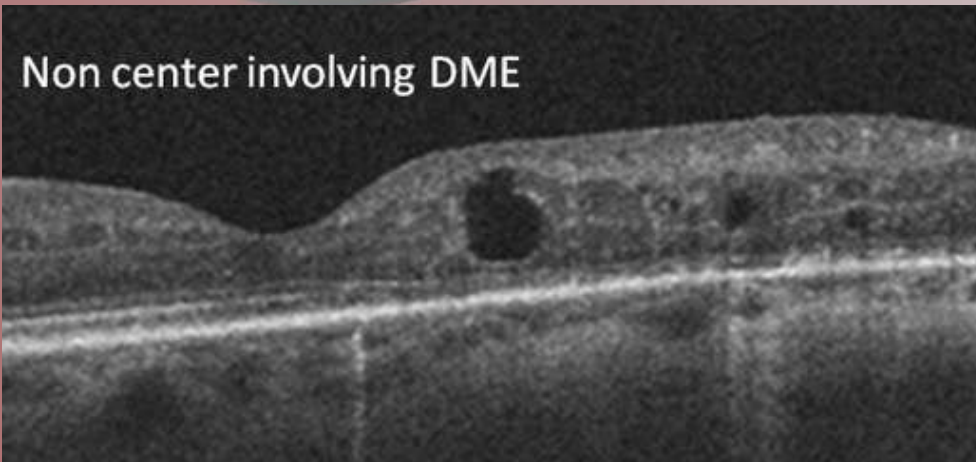
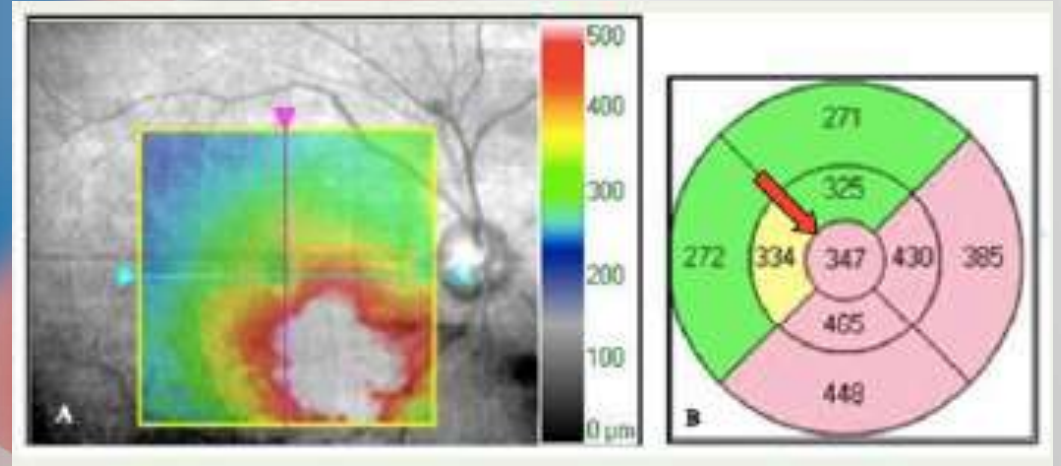
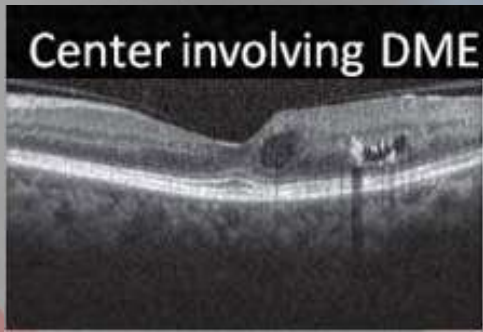


Diabetic Retinopathy: Macular Edema

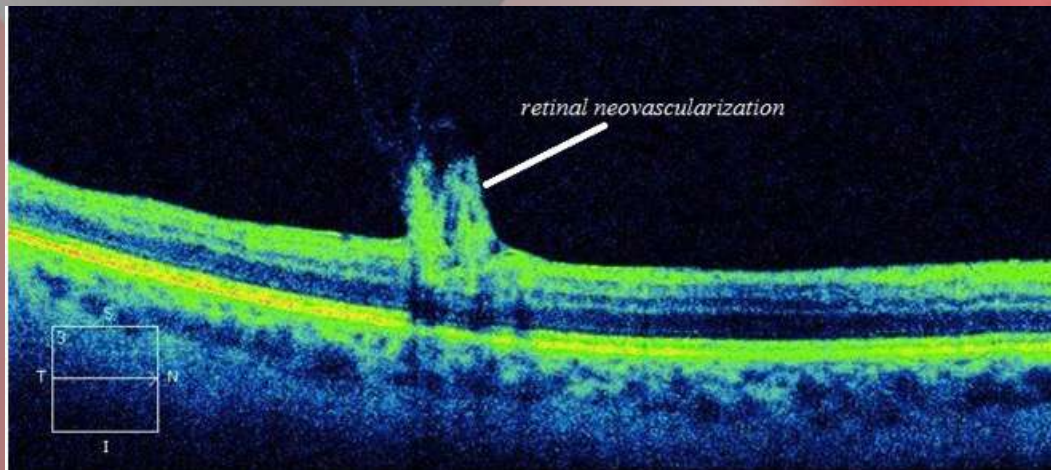
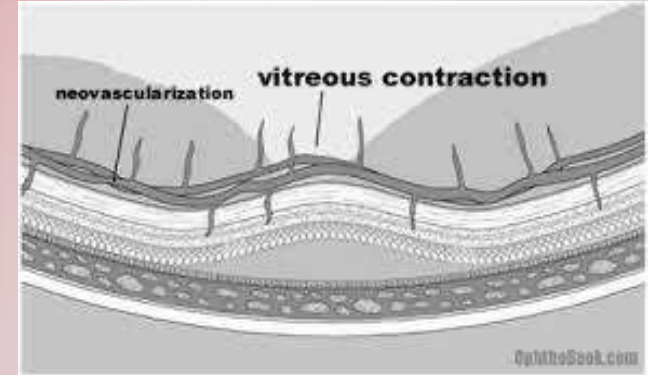
HYPO-Reflective: Serous Fluid



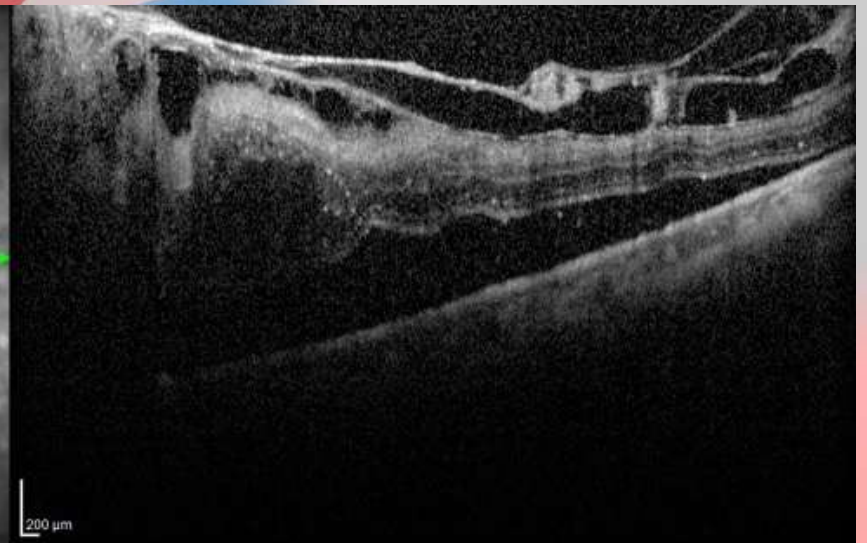
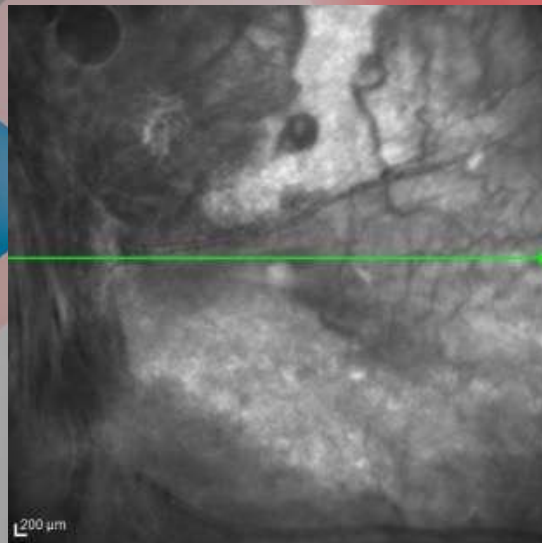
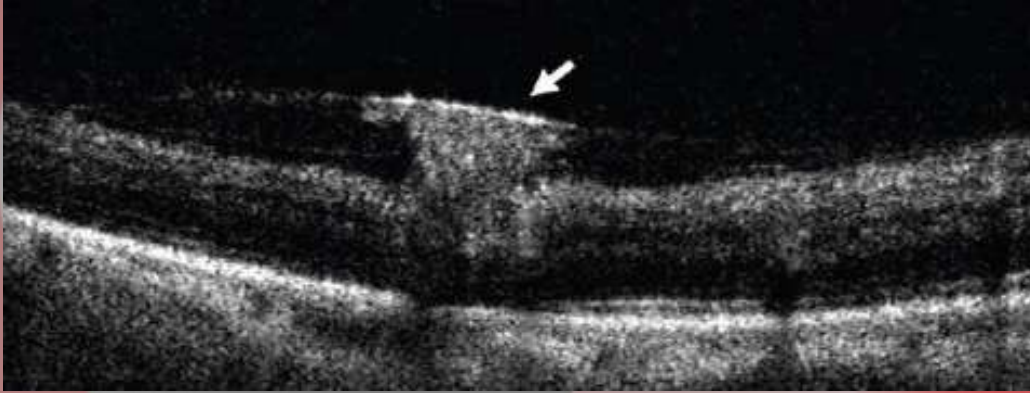
Macular Edema: CI versus NCI



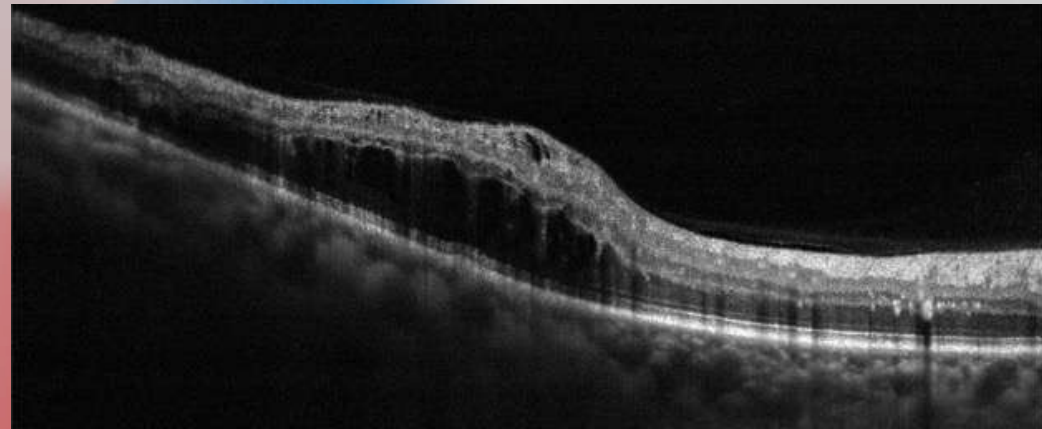
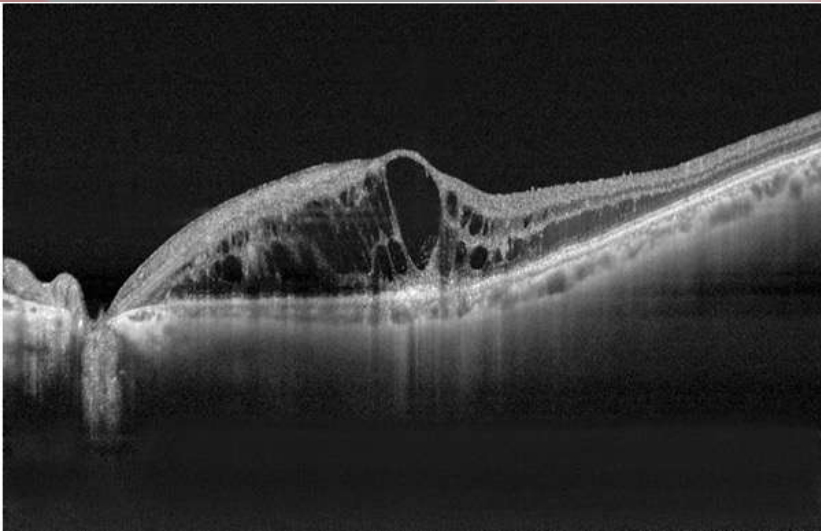
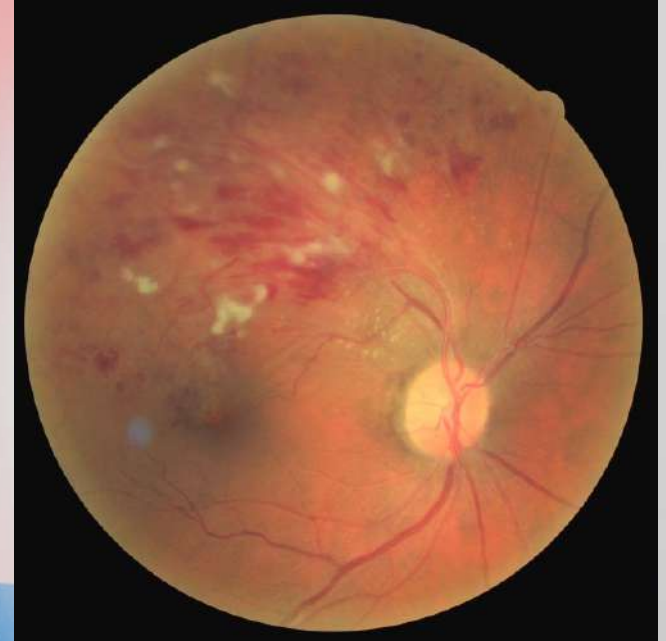
Diabetic Retinopathy: Proliferative



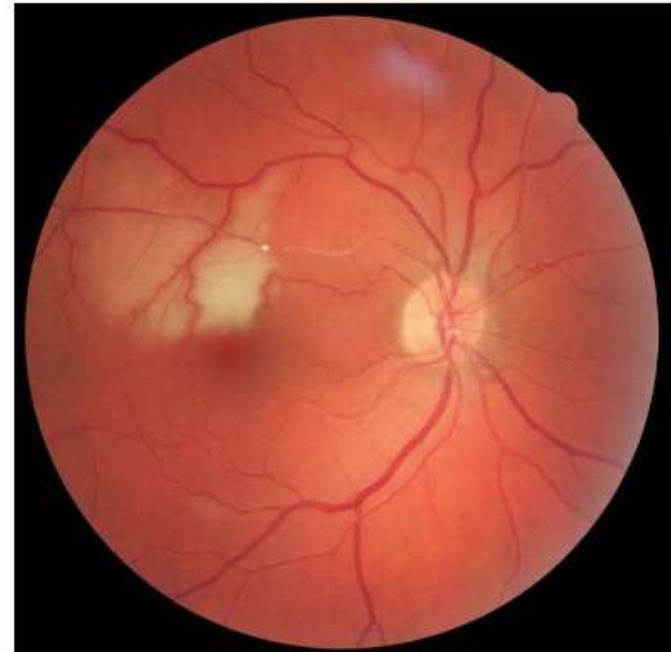
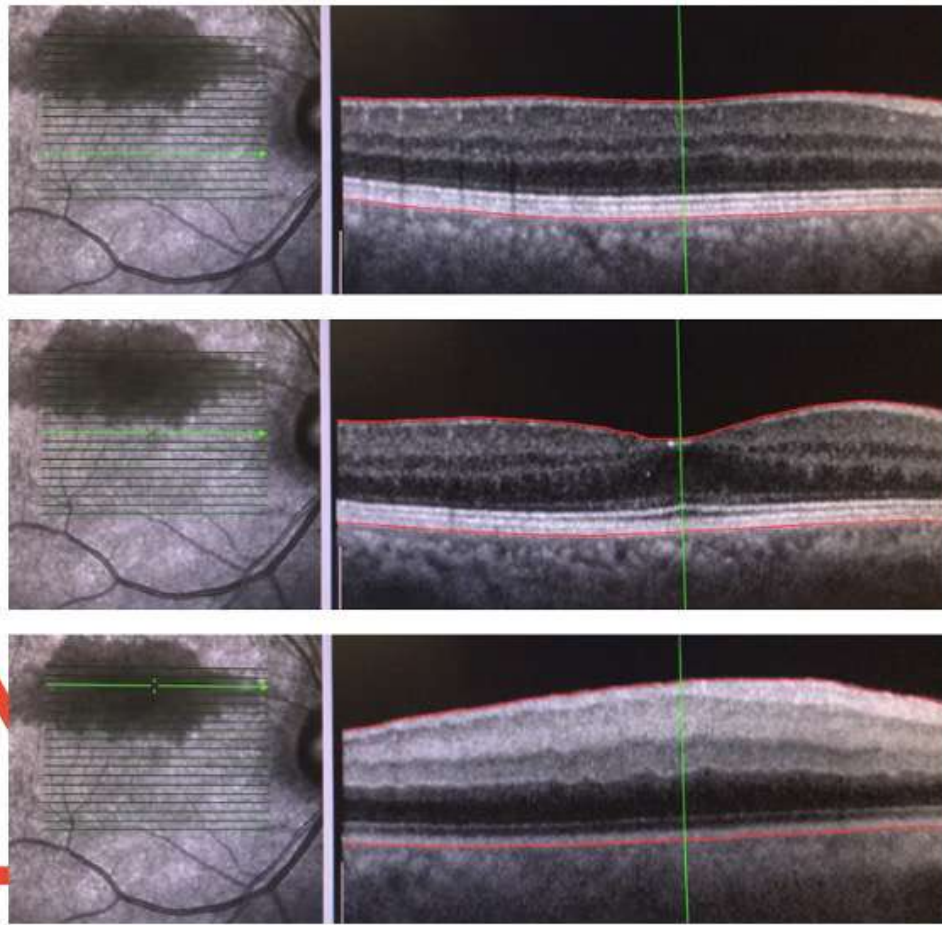
Diabetic Retinopathy: Proliferative



Vein Occlusion



Artery Occlusion: Acute

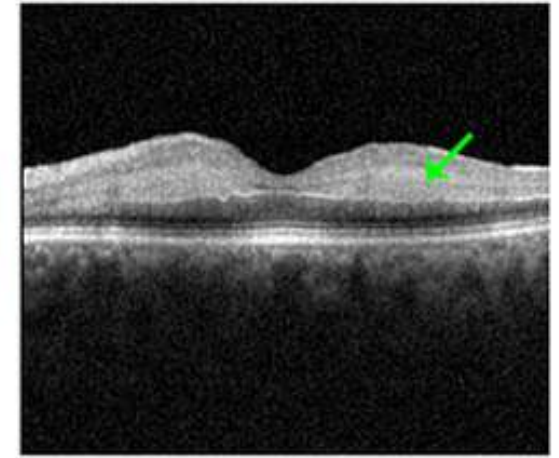
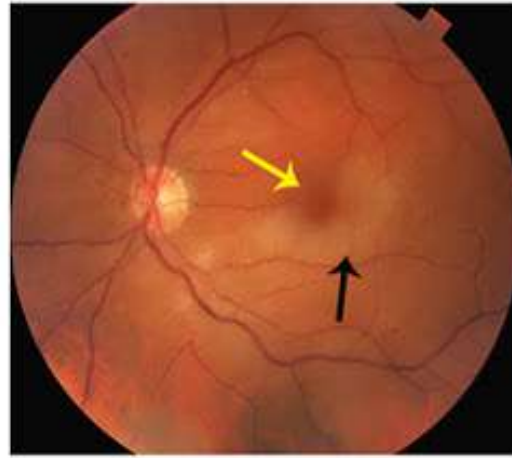


<http://eyesteve.com/branch-retinal-artery-occlusion/>

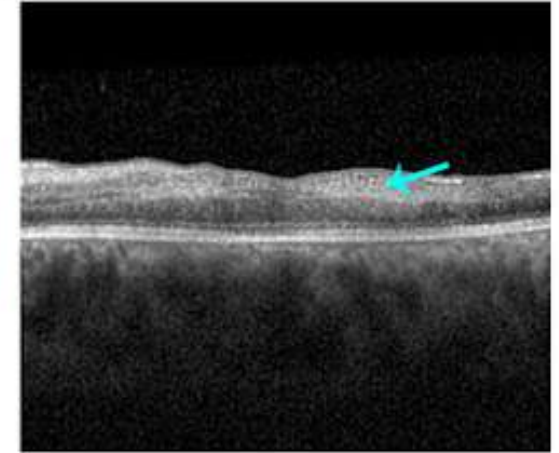
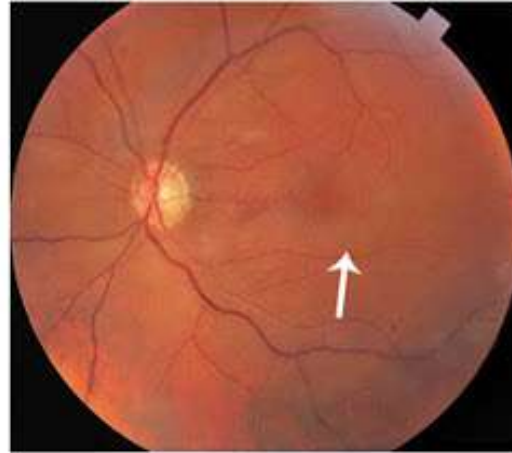
Artery Occlusion:

Chronic

2-24-2017

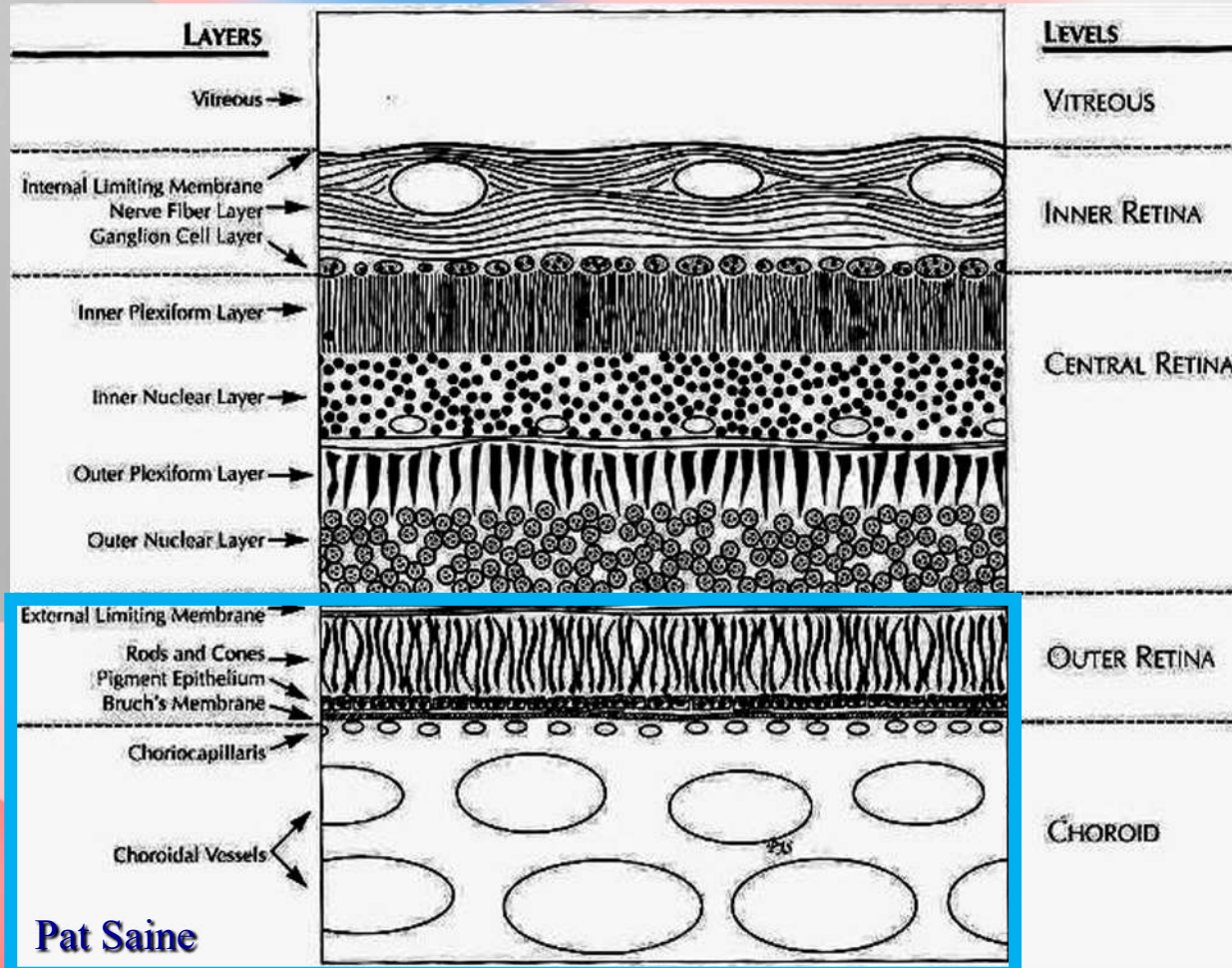


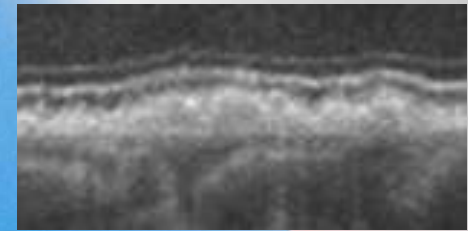
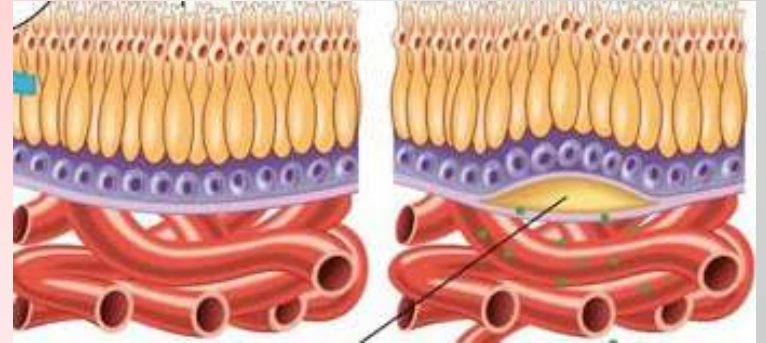
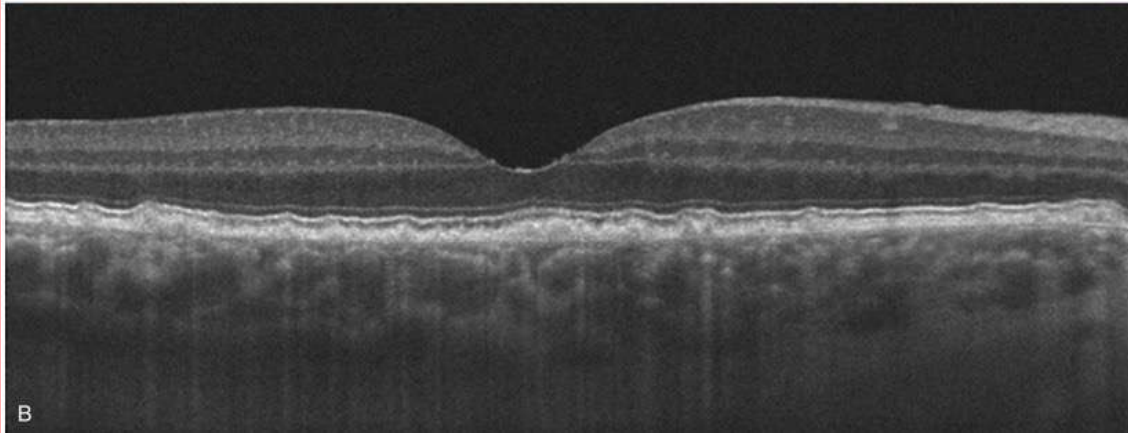
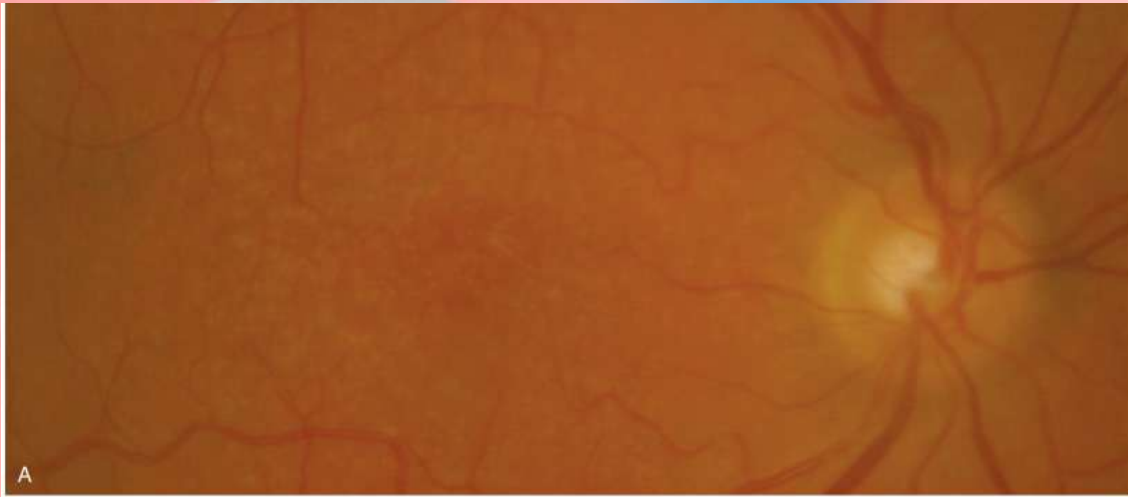
3-24-2017



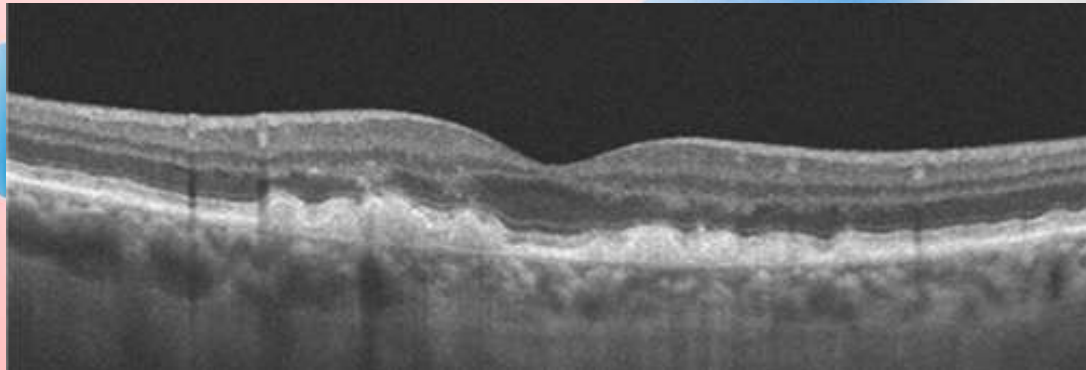
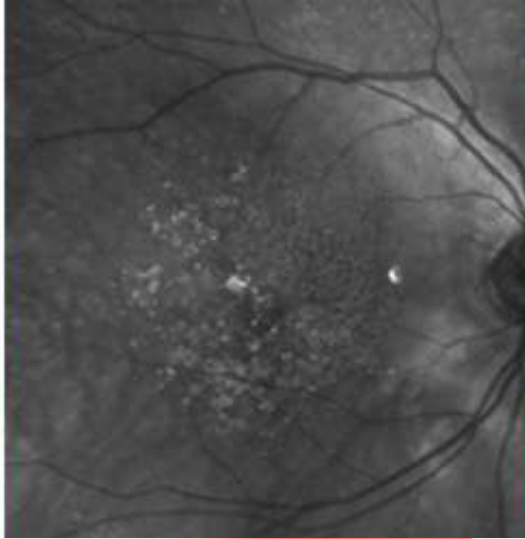
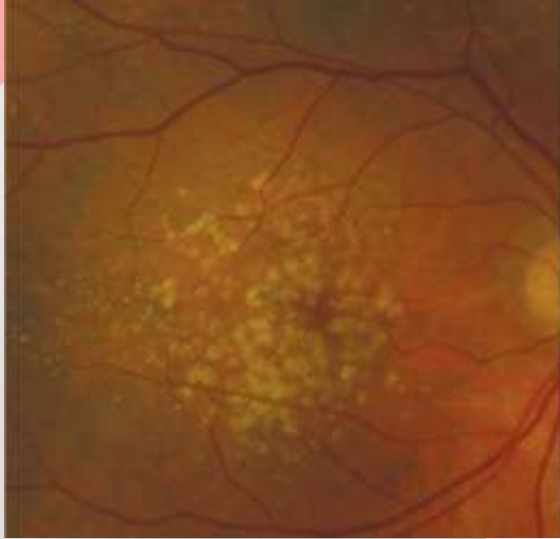


Outer Retinal Disease

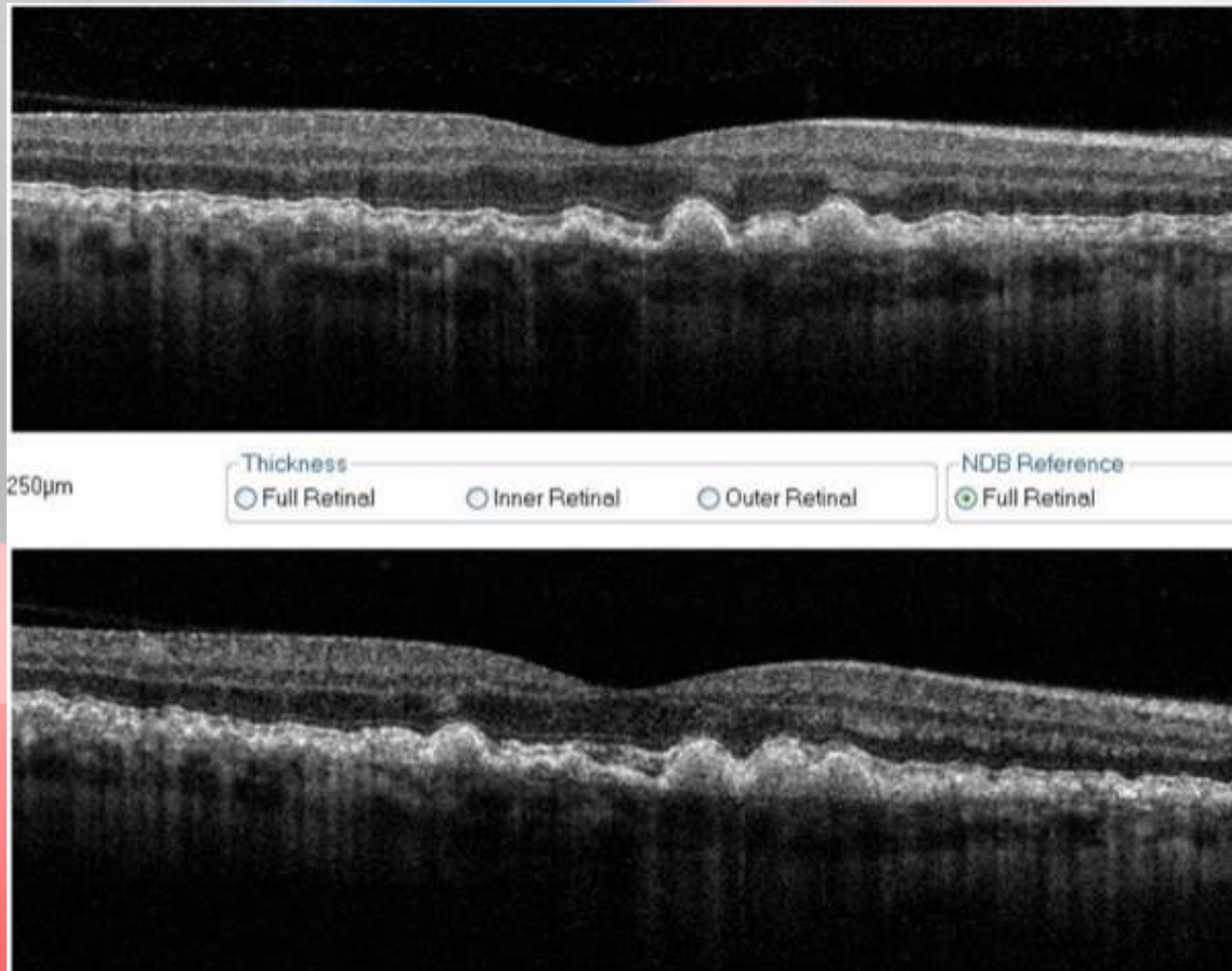




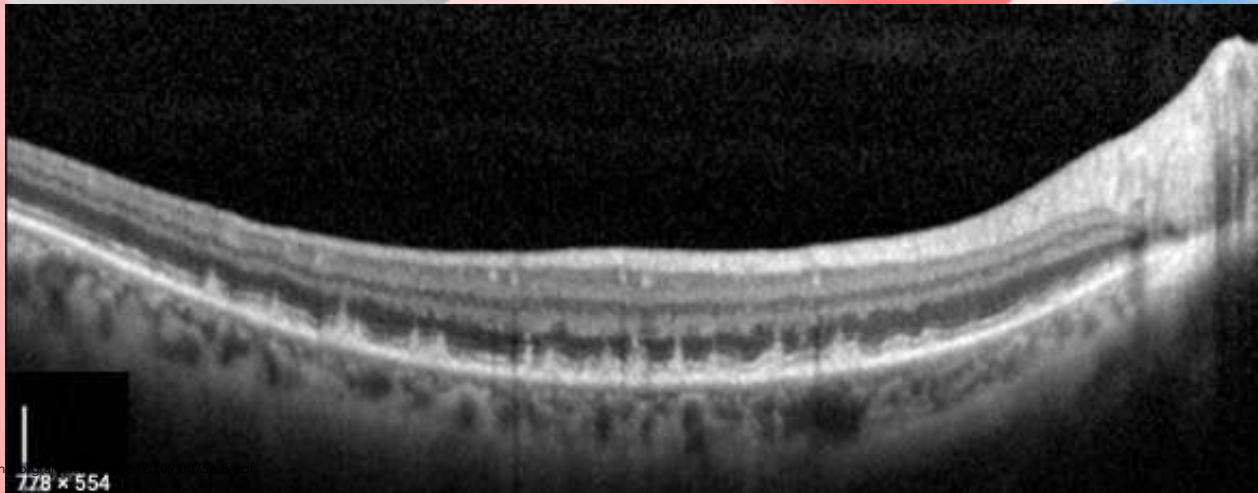
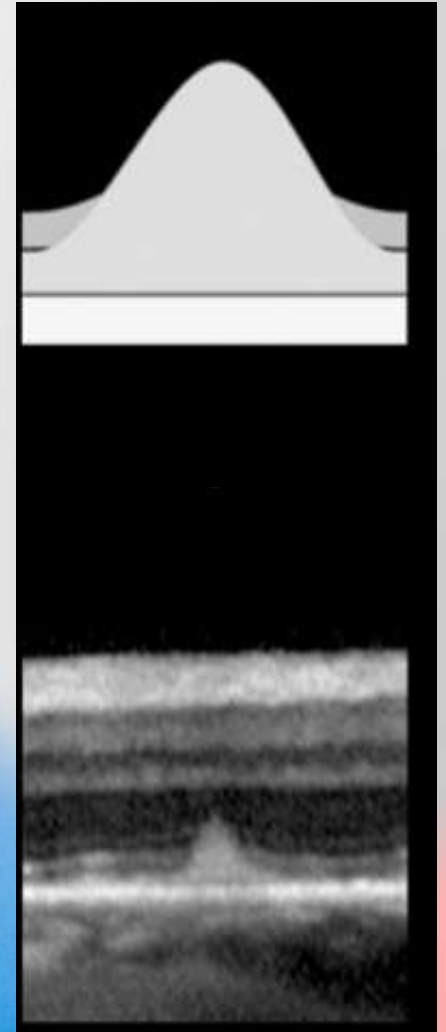
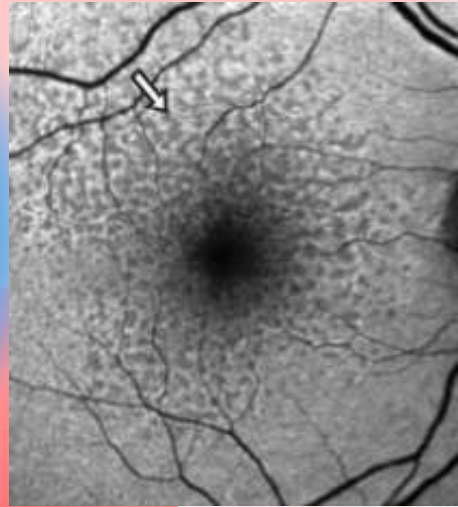
Drusen



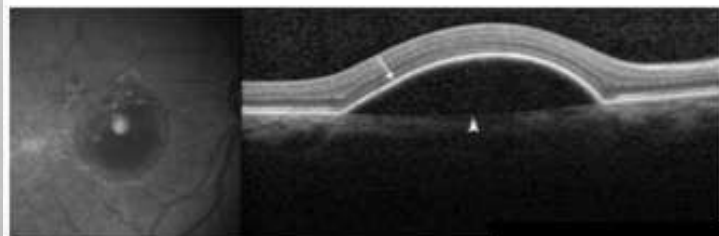
Change Analysis



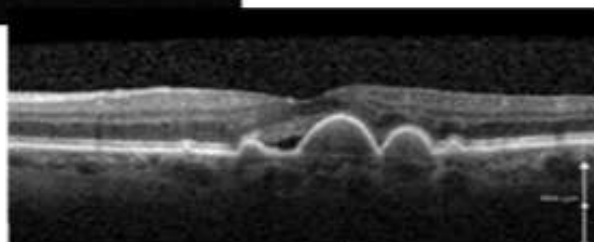
Reticular Pseudodrusen



Pigment Epithelial Detachments

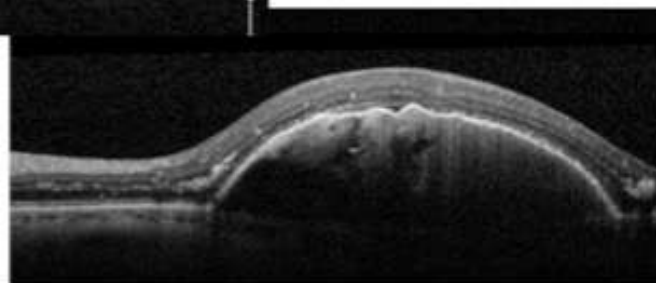


Serous

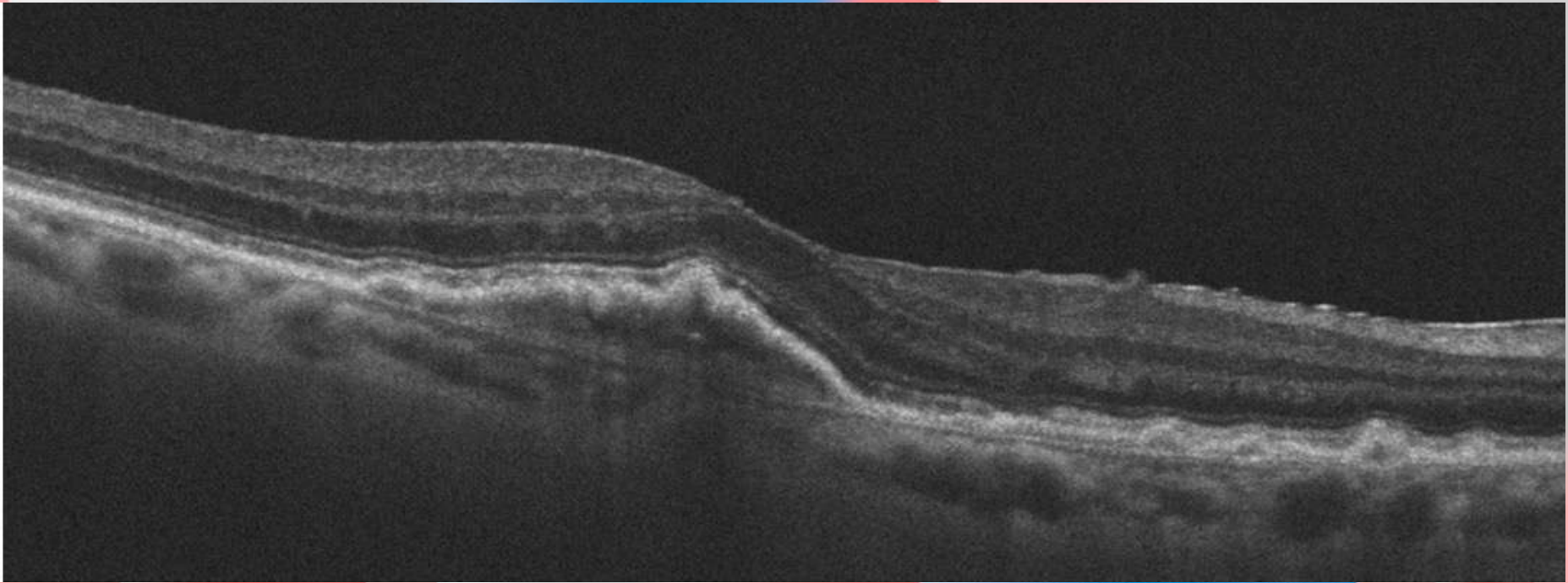


Drusenoid

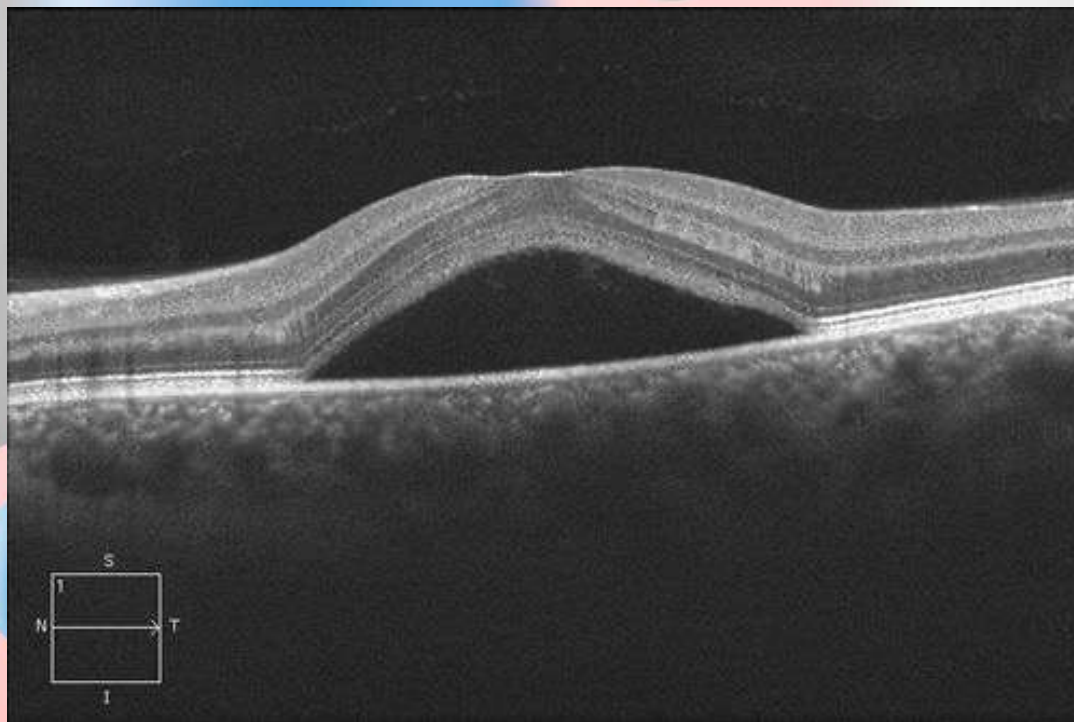
Hemorrhagic



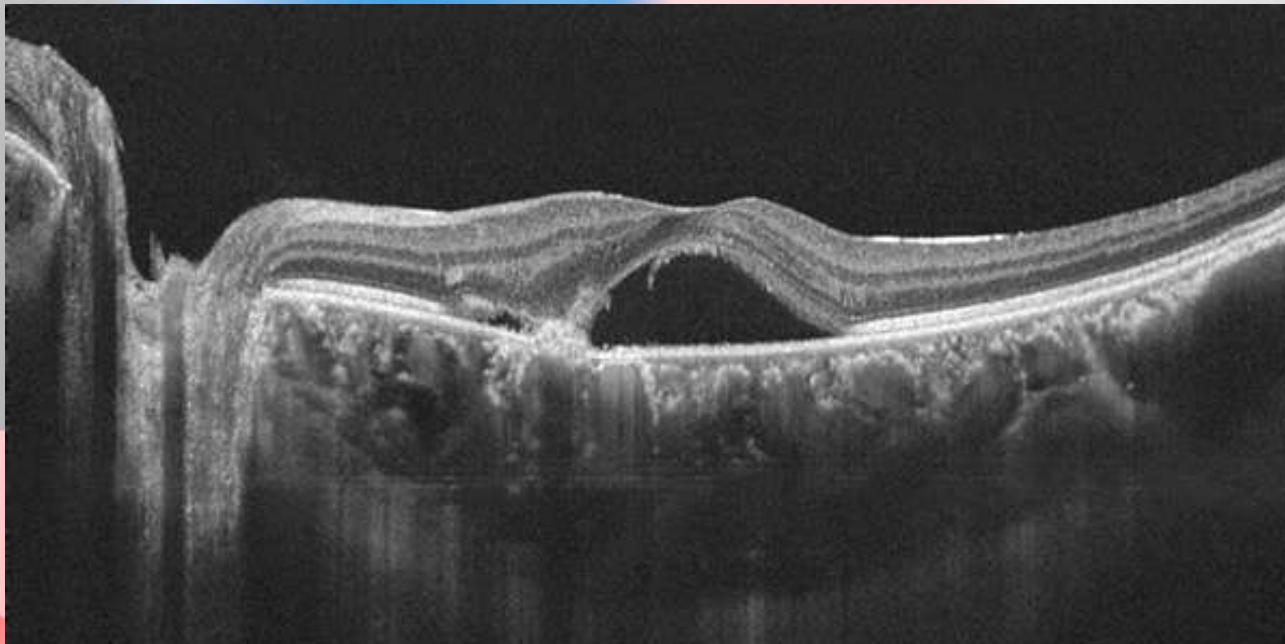
Pigment Epithelial Detachments: What Kind?



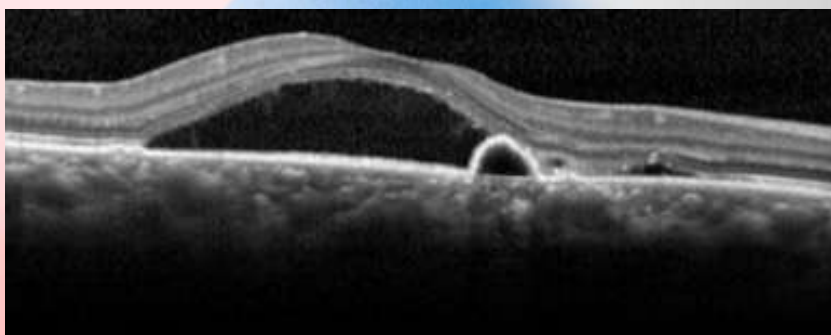
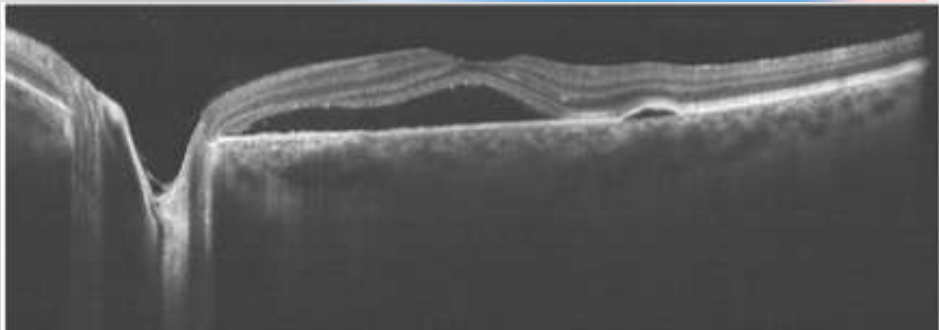
Central Serous Chorioretinopathy



Central Serous Chorioretinopathy: Chronic

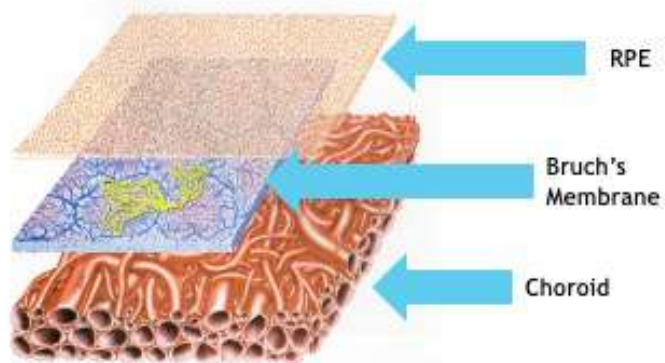


Central Serous Chorioretinopathy and PED

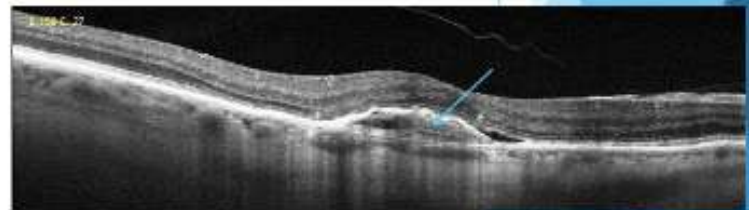


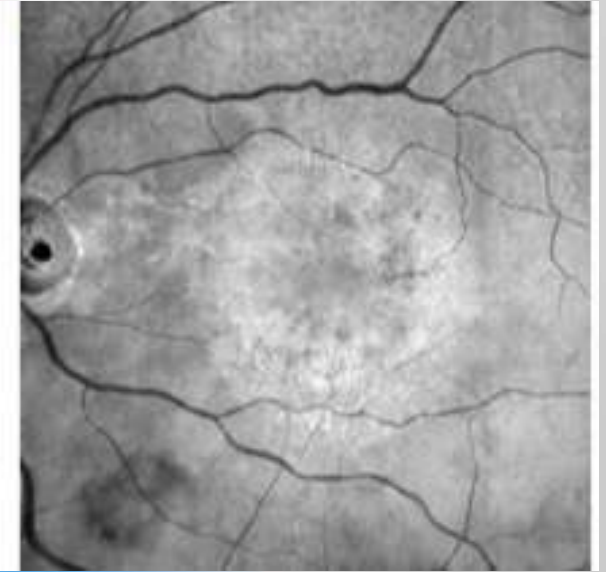
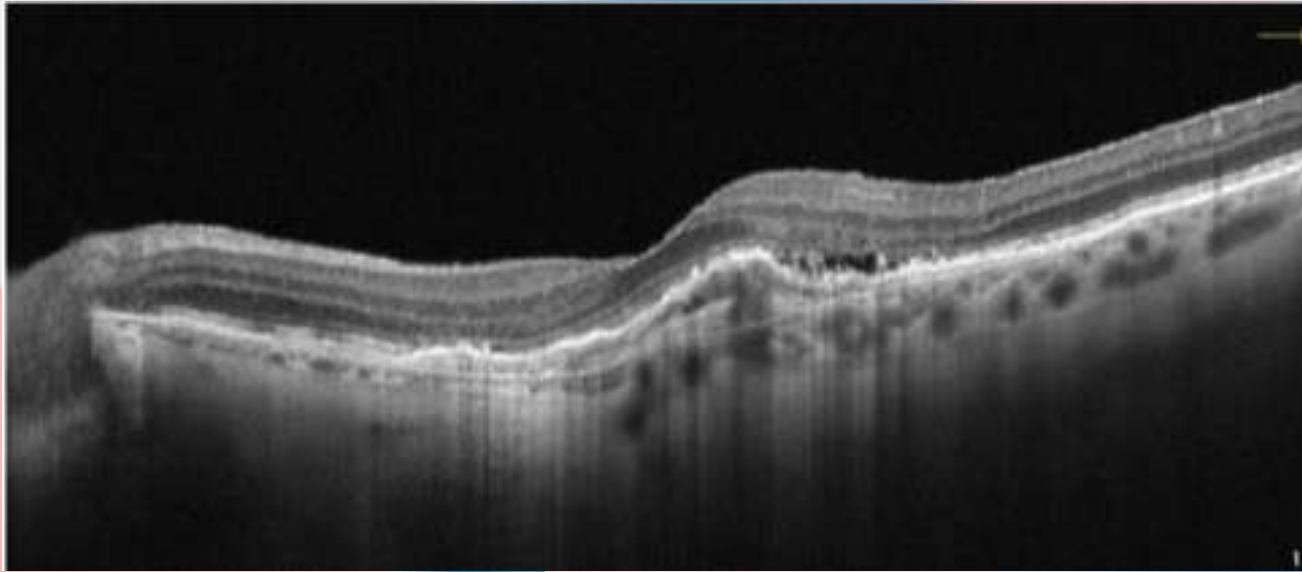
Age Related Macular Degeneration

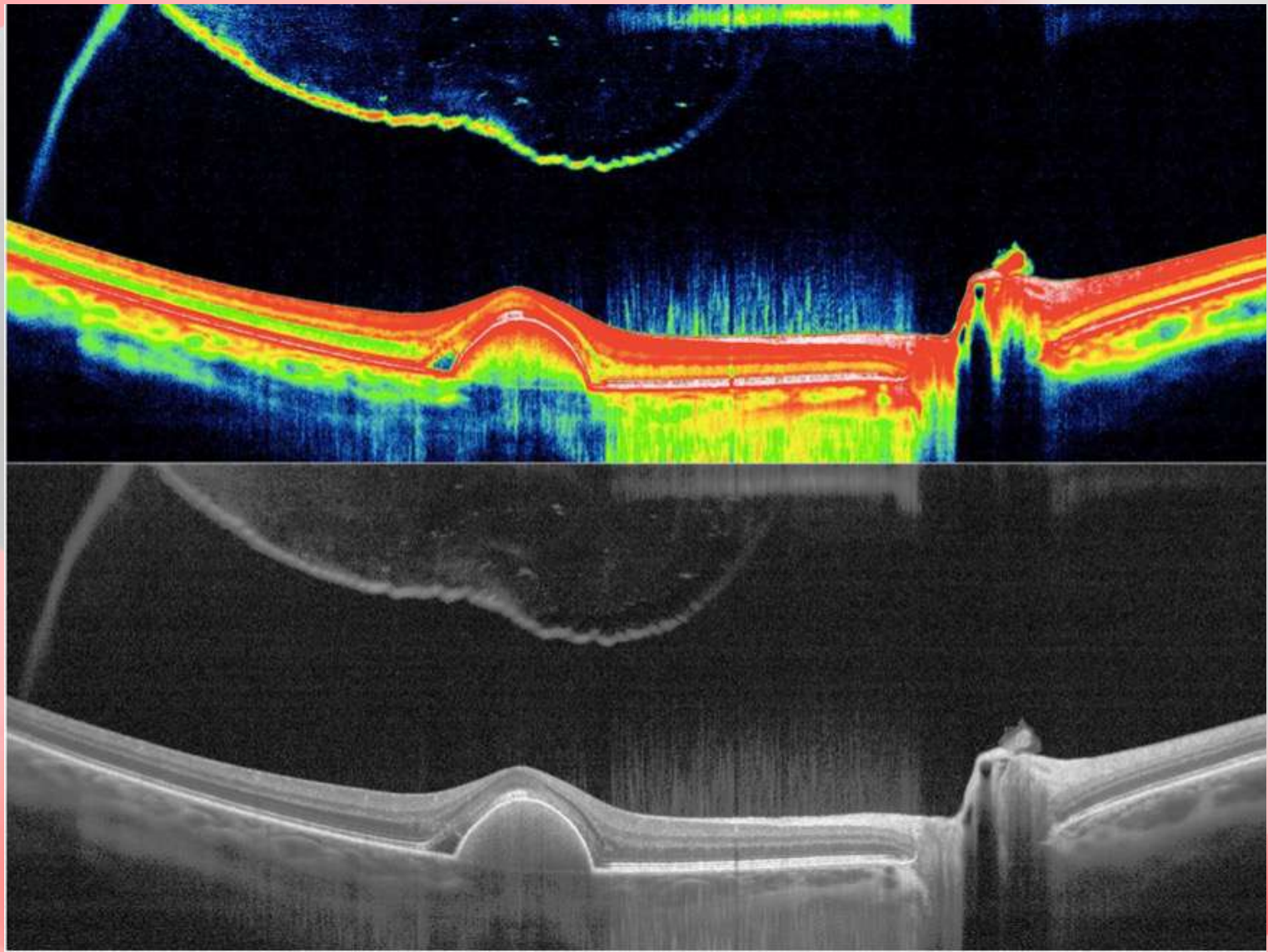
Type 1 "Occult" CNV



- ▶ New vessels develop in the choroid
- ▶ New vessels located **BELOW RPE** and **ABOVE** Bruch's membrane

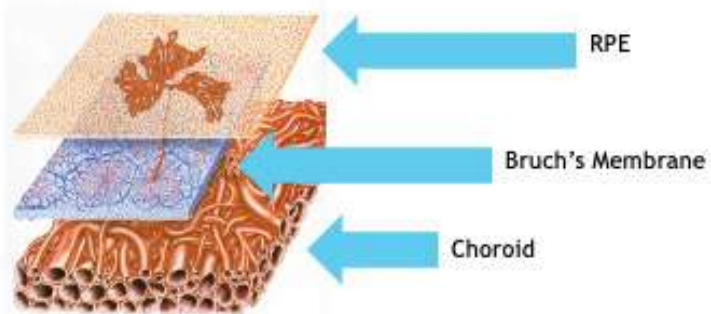




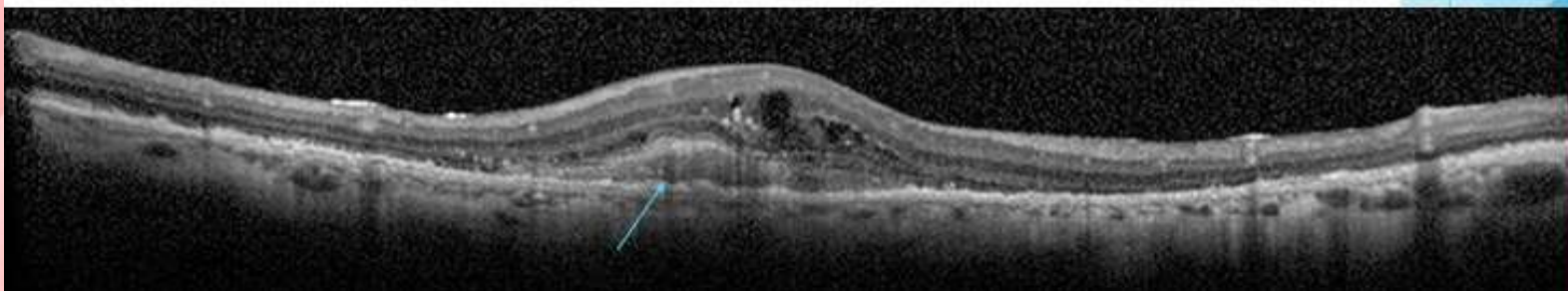


Age Related Macular Degeneration

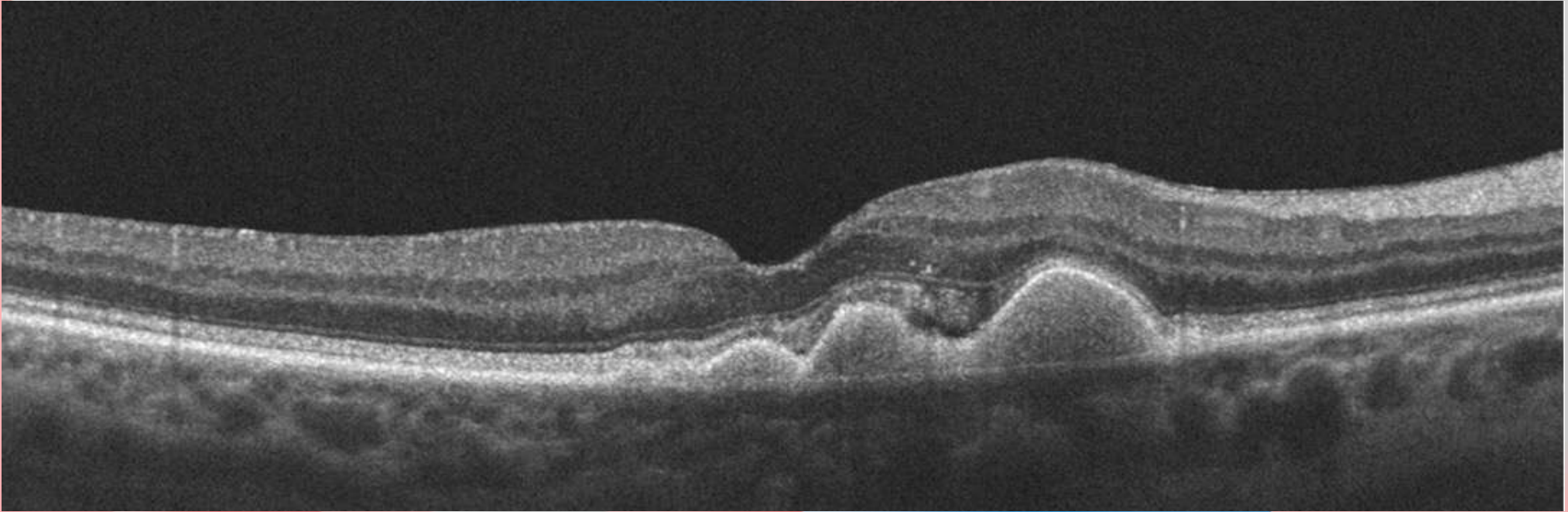
Type 2 "Classic" CNV



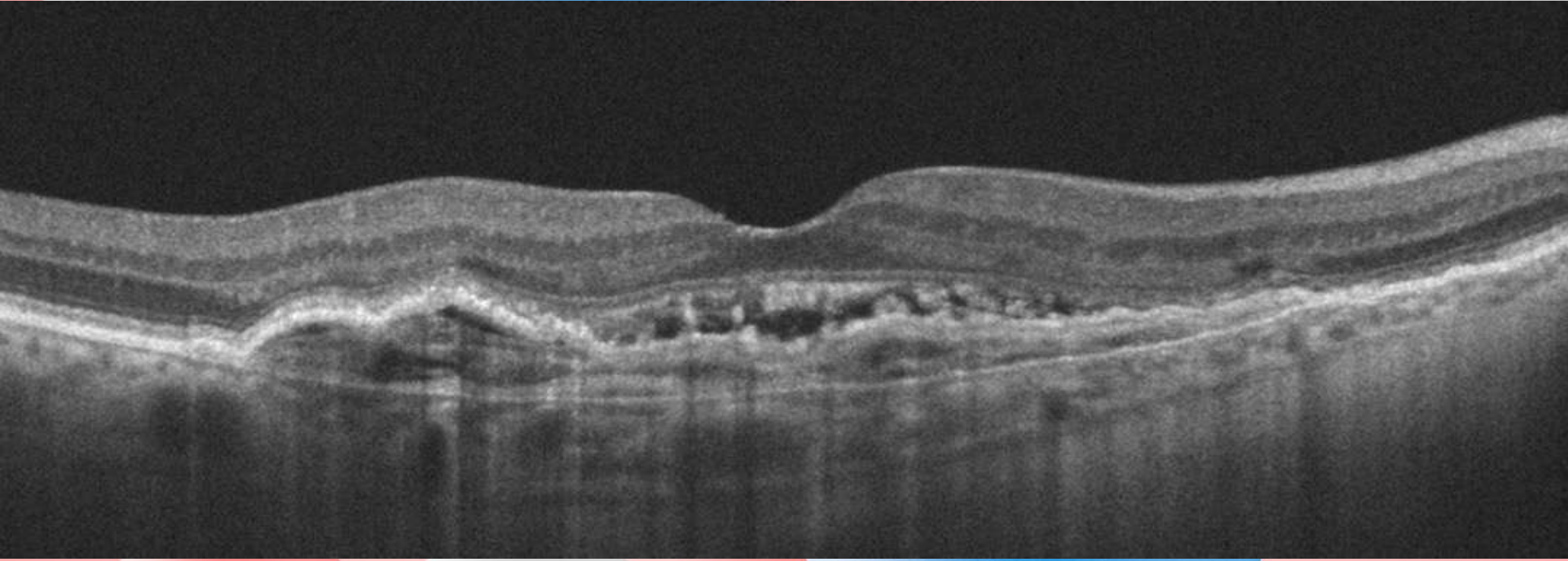
- ▶ New vessels develop in choroid
- ▶ New vessels located **ABOVE** the RPE and ABOVE Bruch's membrane



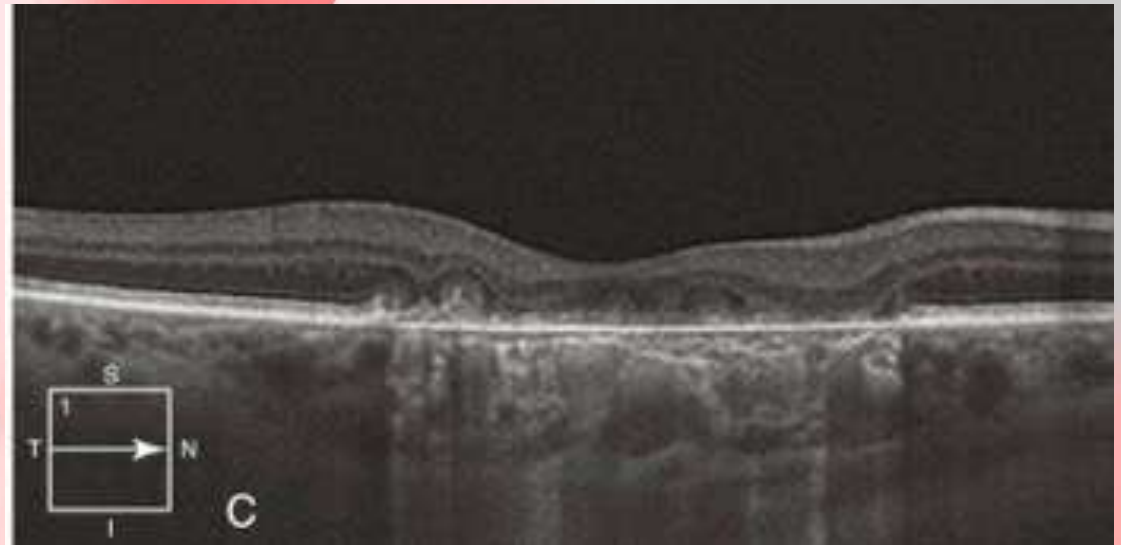
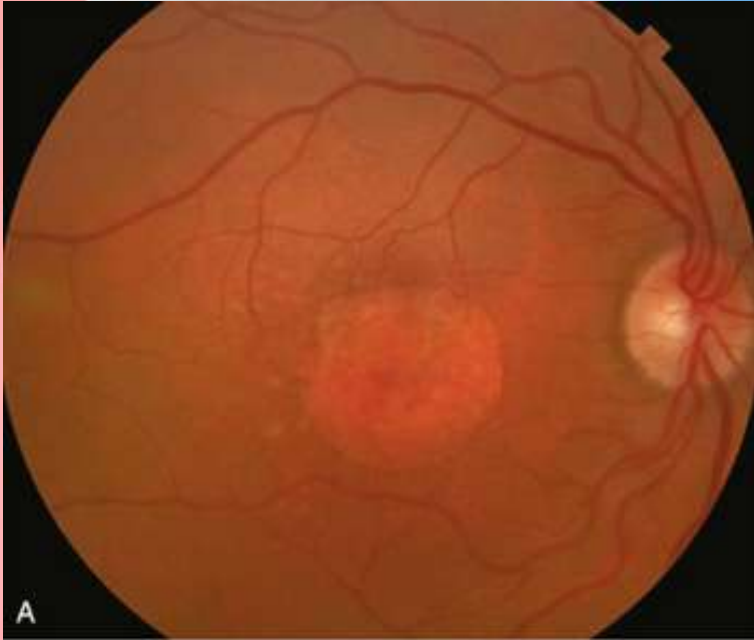
Age Related Macular Degeneration

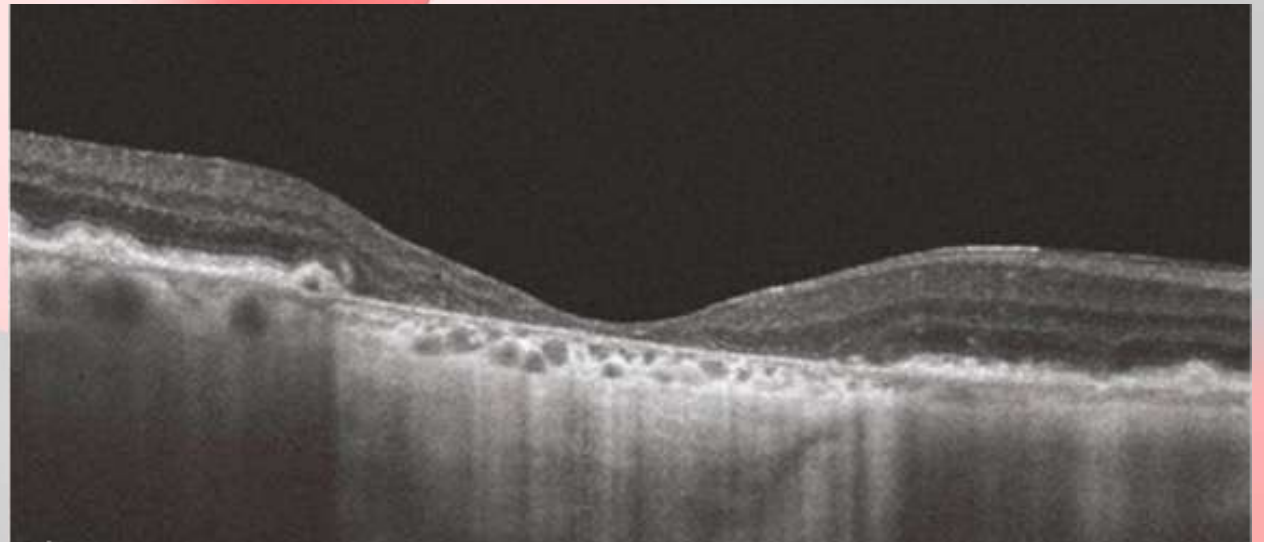
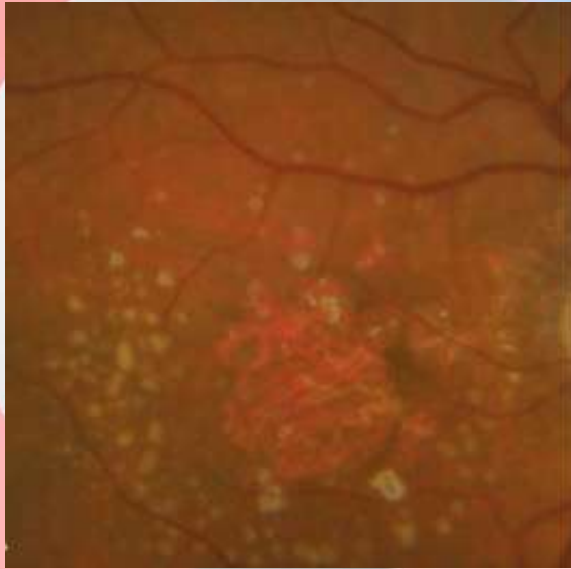


Age Related Macular Degeneration



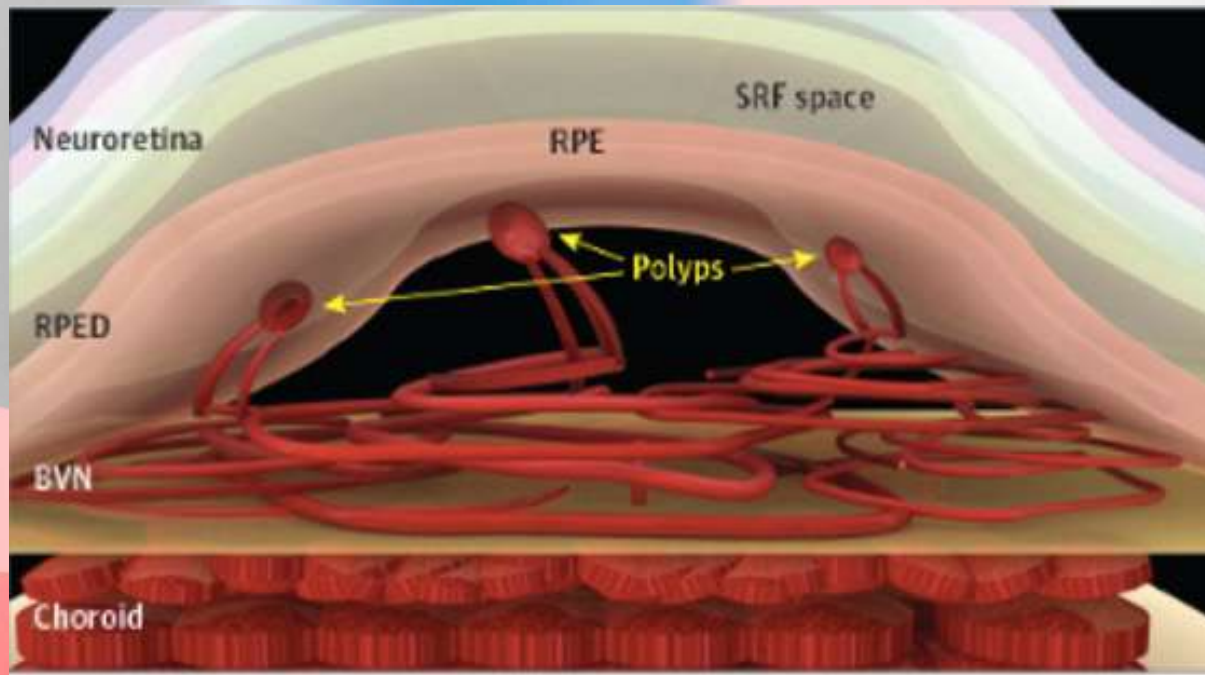
Geographic Atrophy



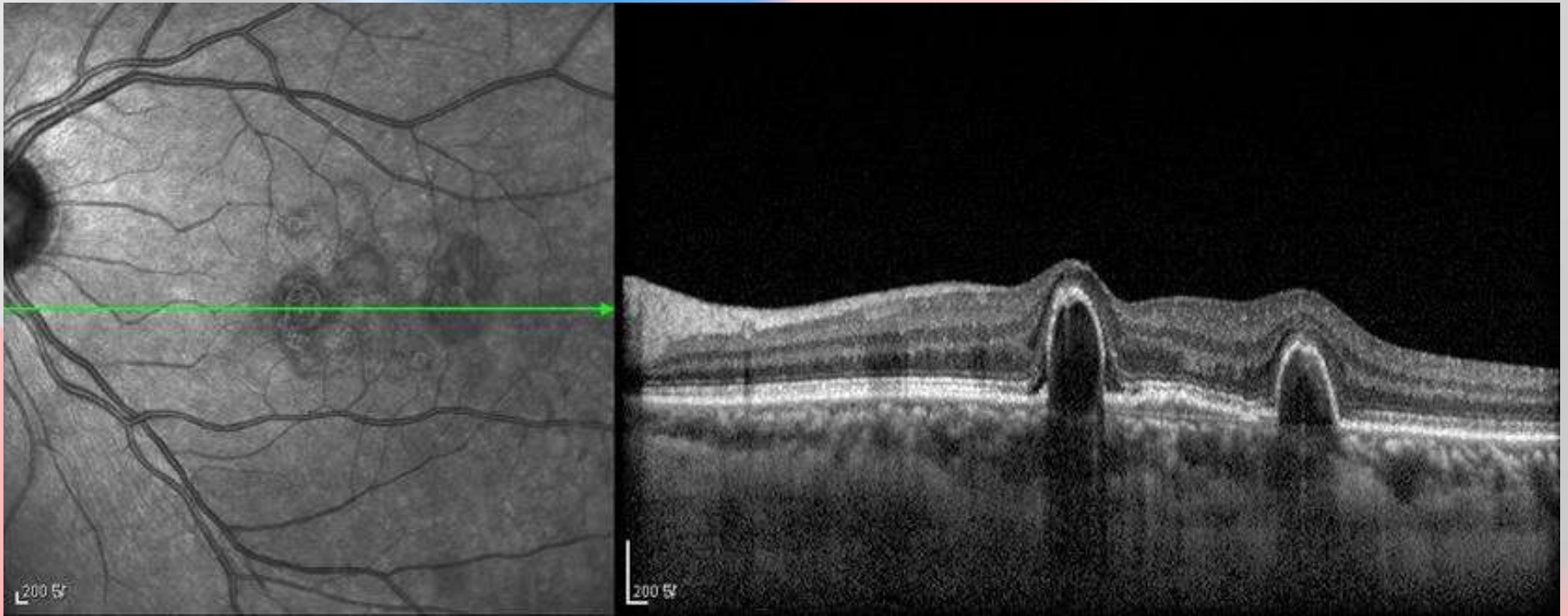


Pachychoroid Clinical Spectrum

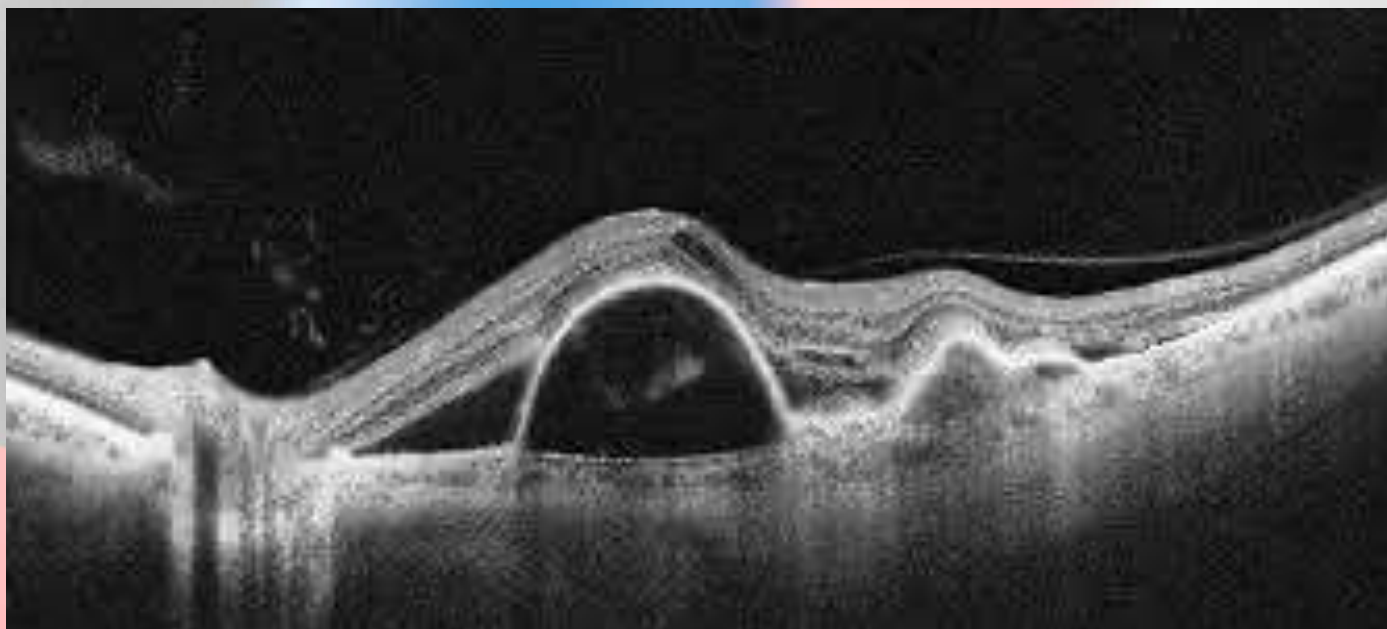
❖ *Polypoidal Choroidal Vasculopathy*



❖ *Polypoidal Choroidal Vasculopathy*

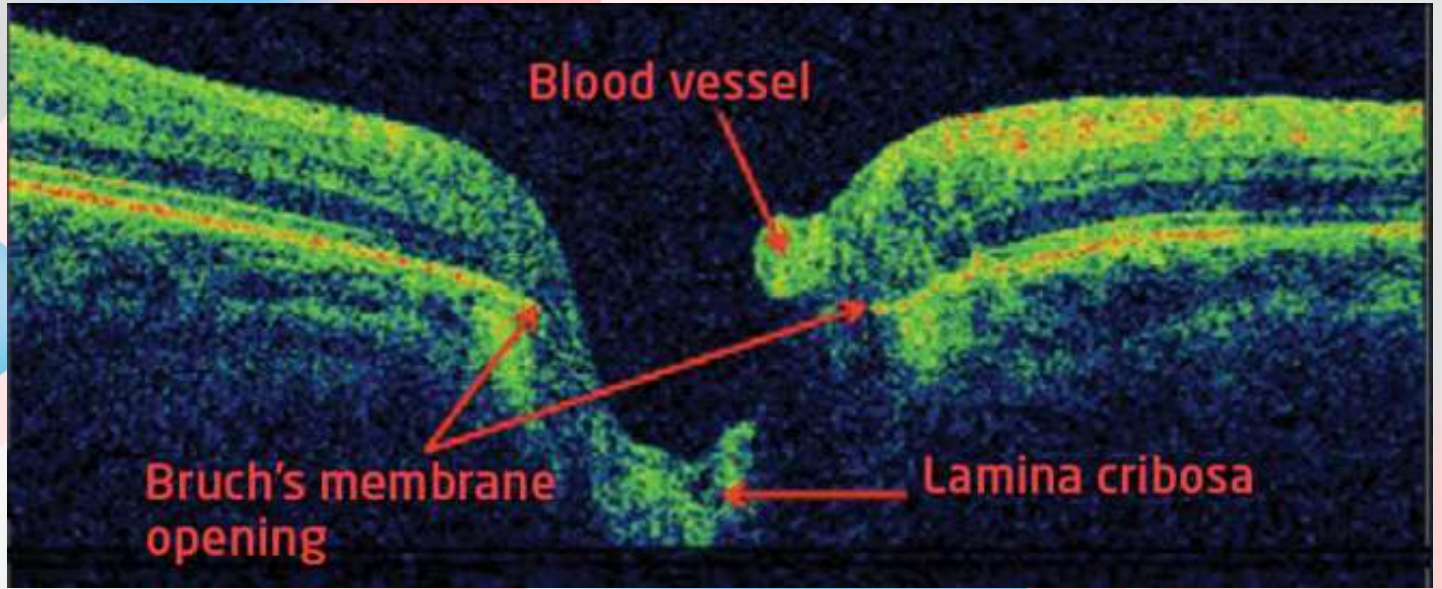
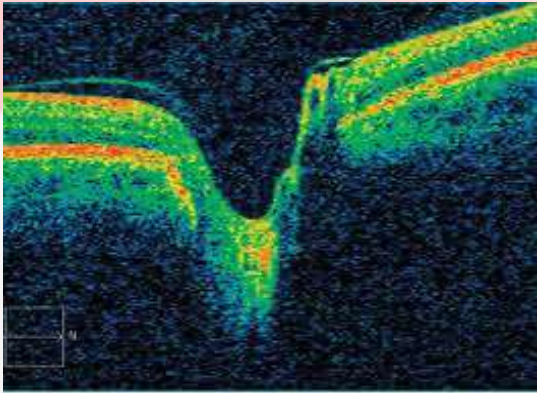


❖ *Polypoidal Choroidal Vasculopathy*





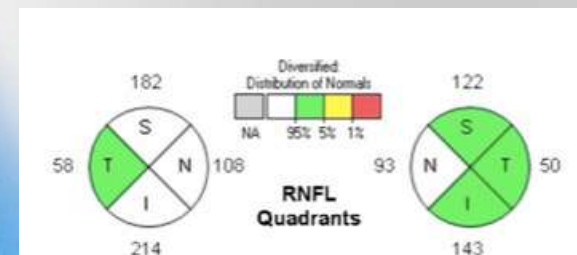
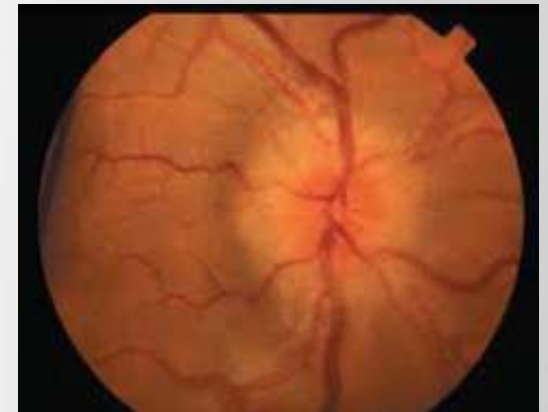
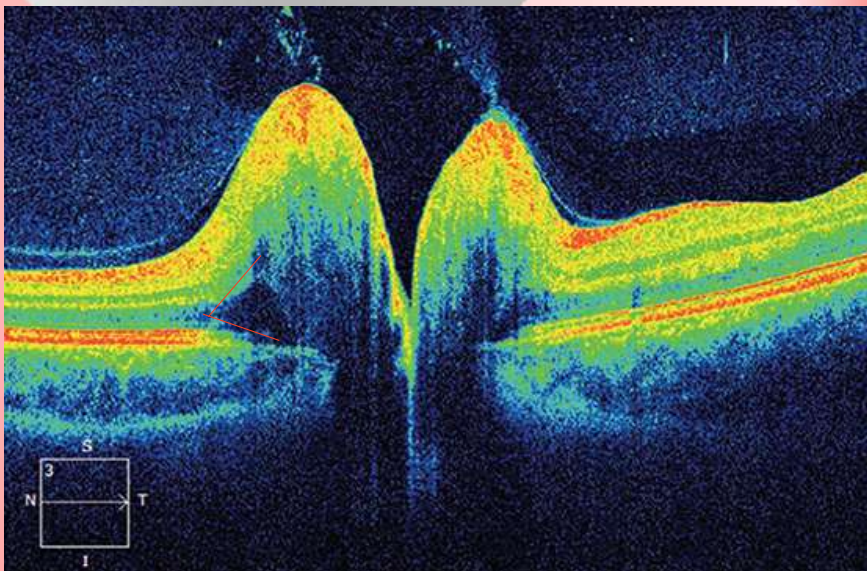
Optic Nerve OCT



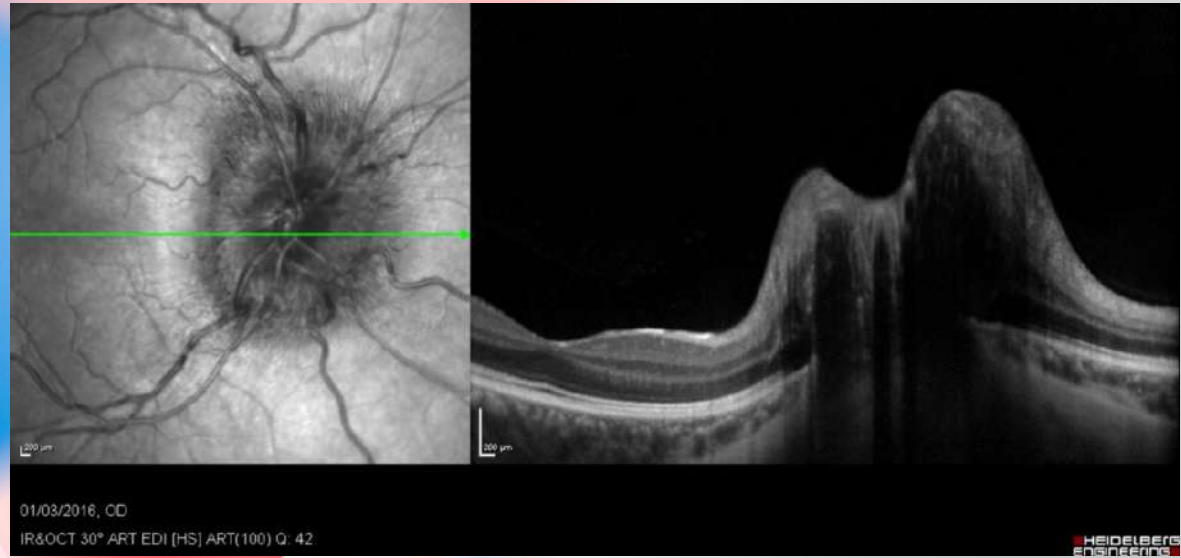
Papilledema

Important features of disc edema on OCT:

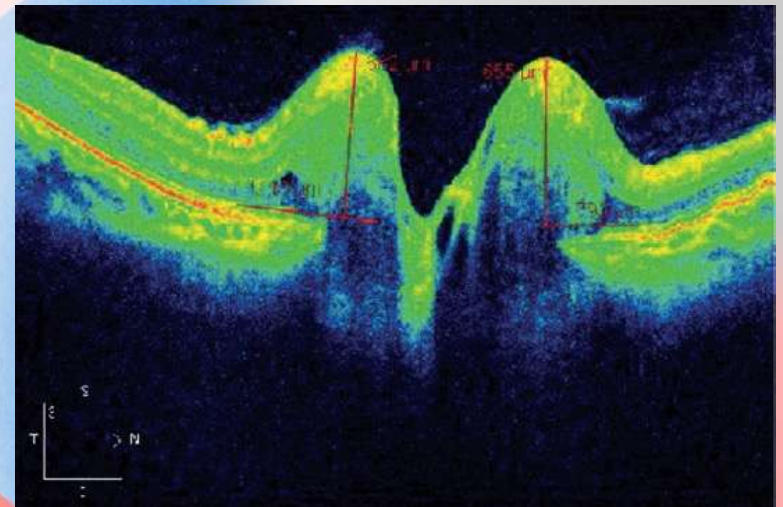
- Smooth contour of elevation
- Nasal RNFL >86 μm
- Thick hypo-reflective space adjacent to disc “lazy V” (Especially nasal)



Papilledema

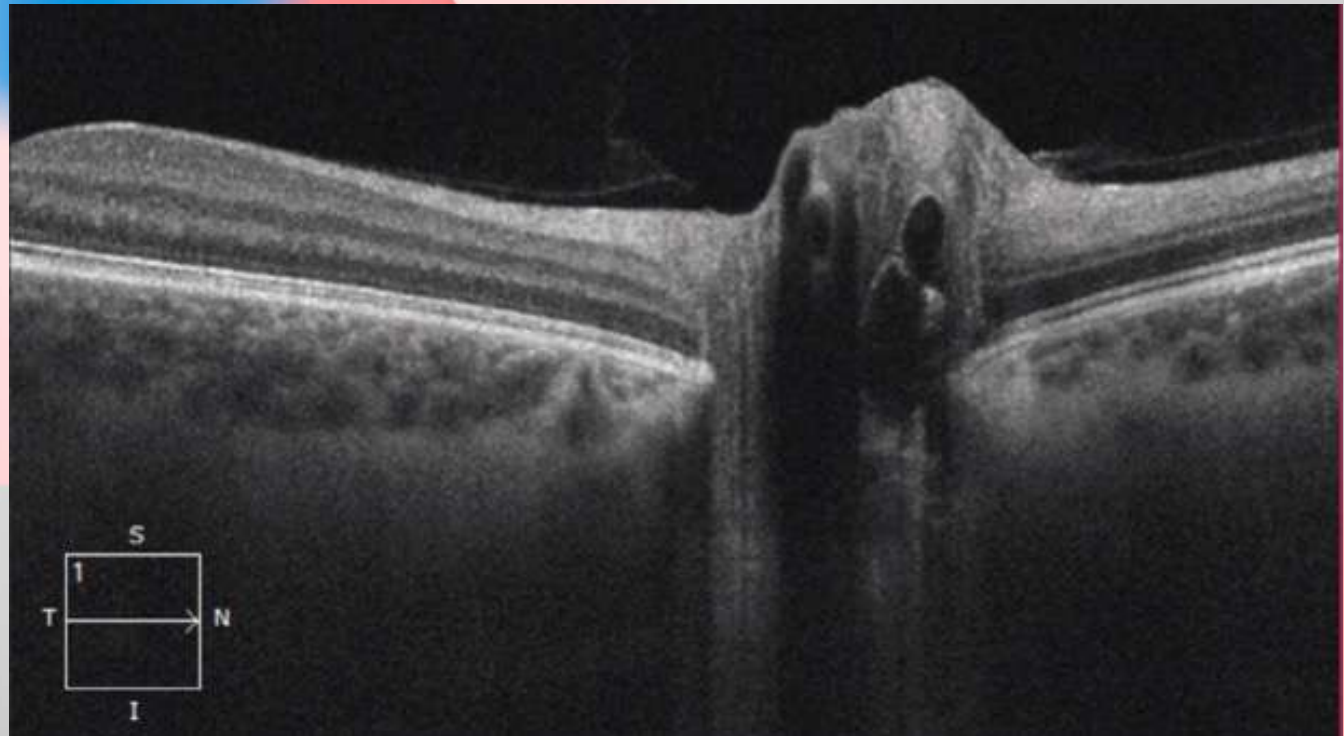
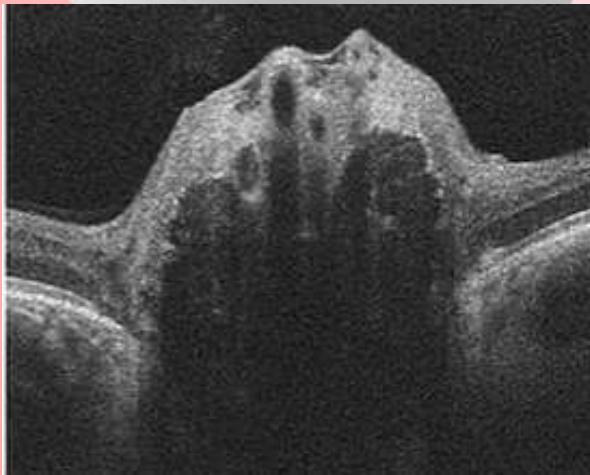


- Increased ICP will push the globe anteriorly
- With EDI, can see an anteriorly displaced Bruch's membrane



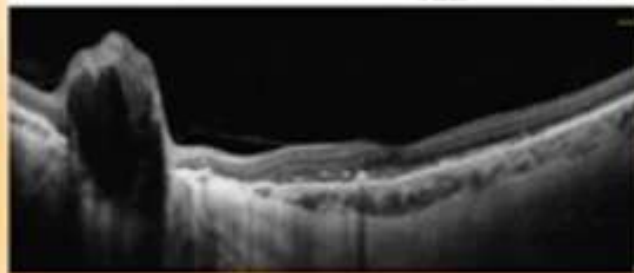
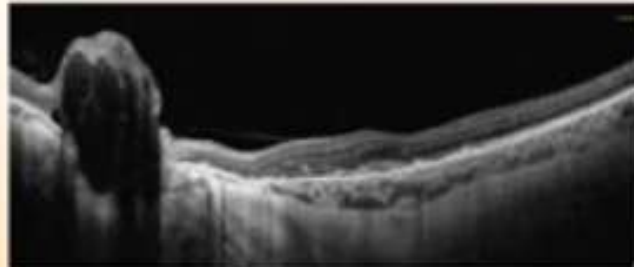
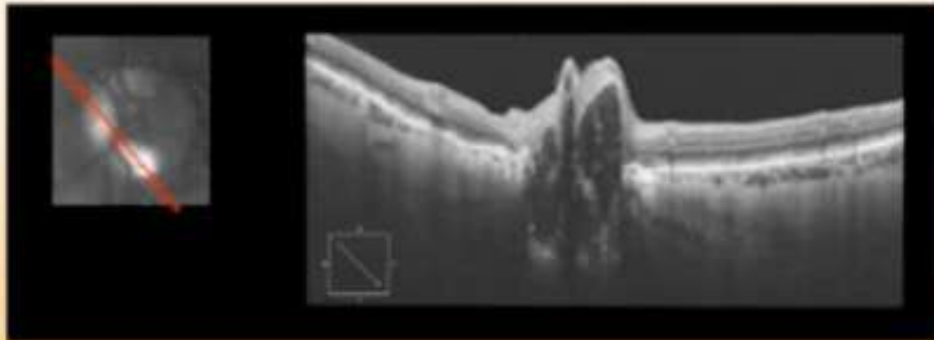
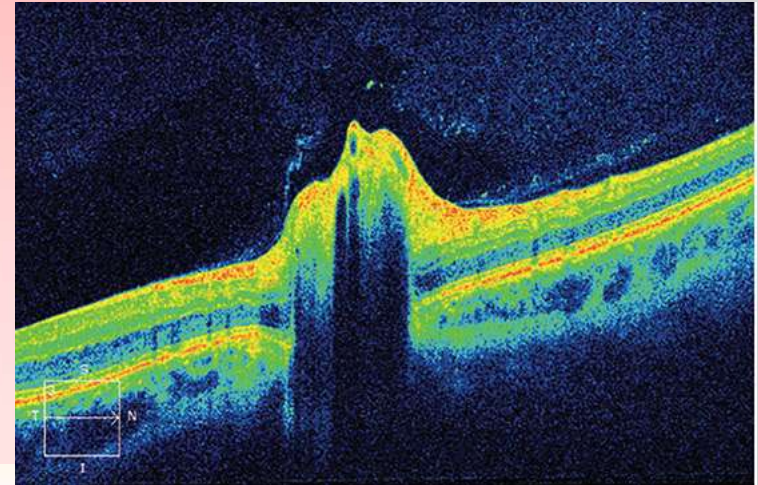
ONH Drusen

Irregular, bumpy contour
Hypo-reflective centers
Hyper-reflective margins



ONH Drusen

Reflectance of Hyaline and Shadowing beneath:
Not seen in cases of papilledema



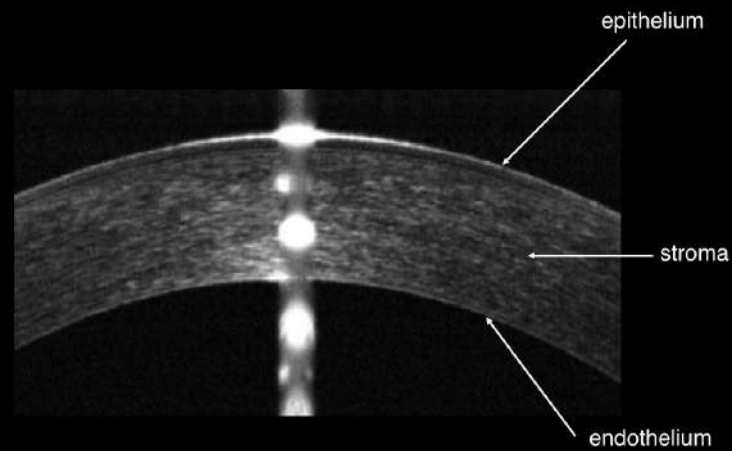


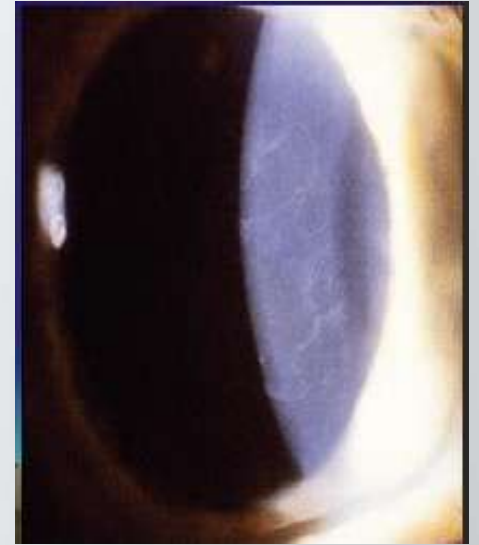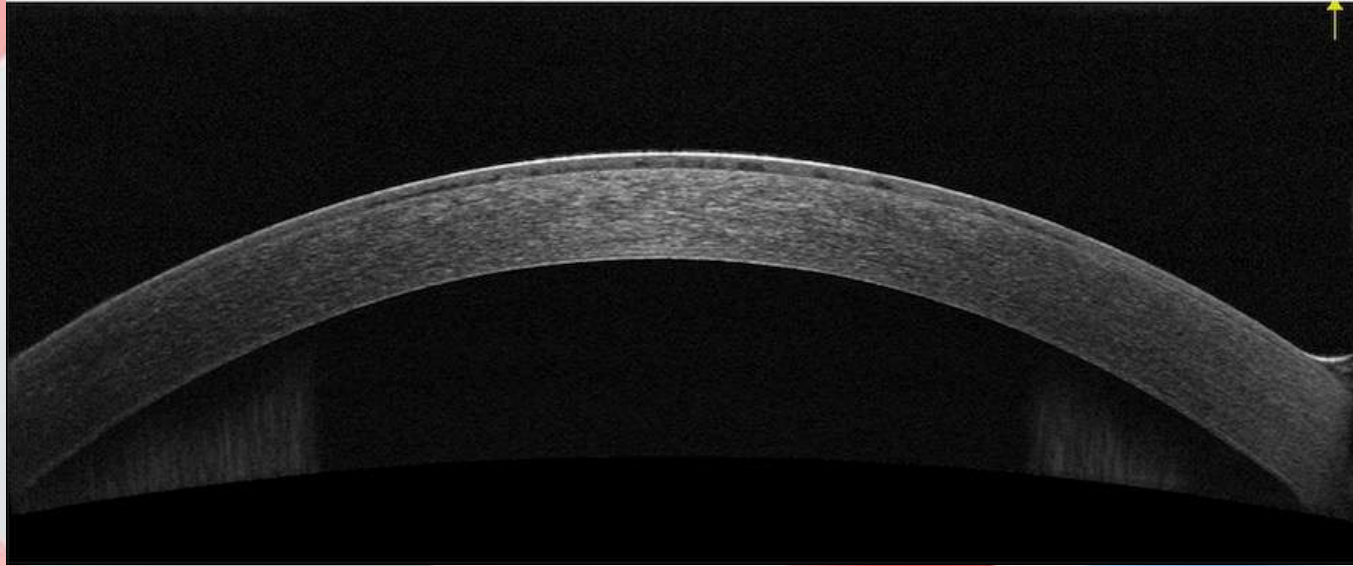
Anatomy of a Corneal OCT Scan

Normal Scan

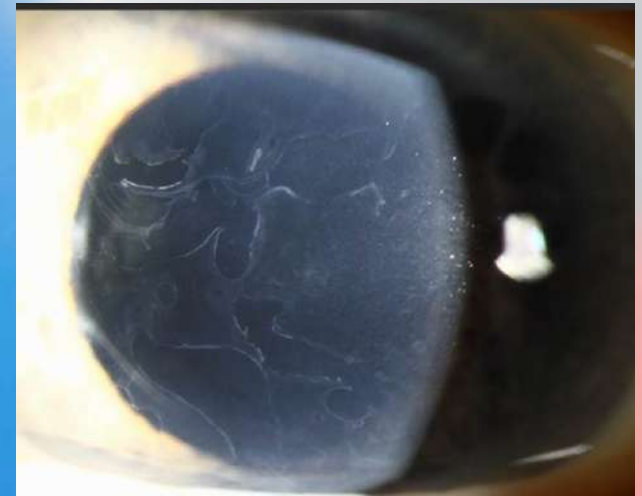
Normal Cornea

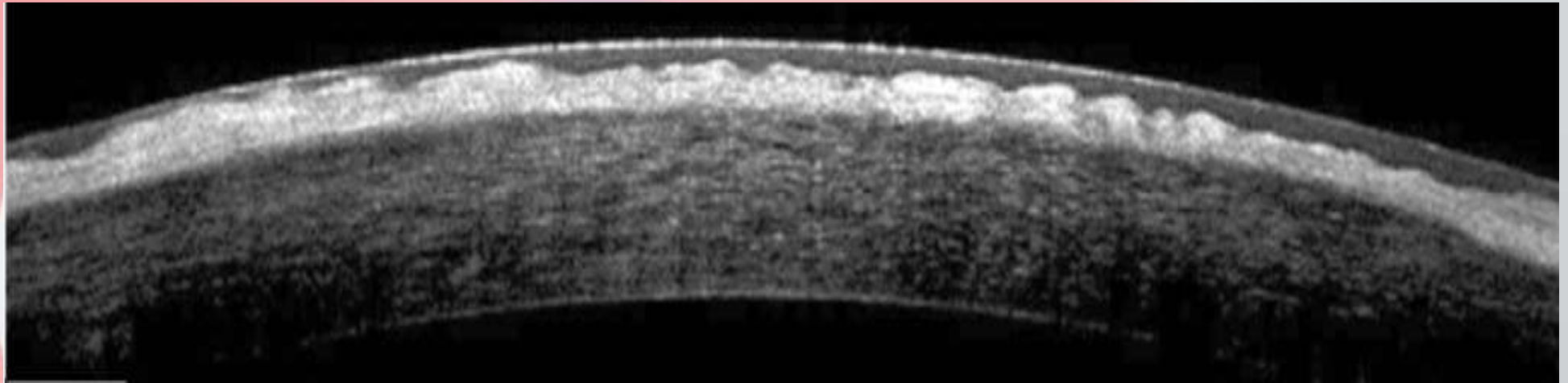
OCT of normal cornea





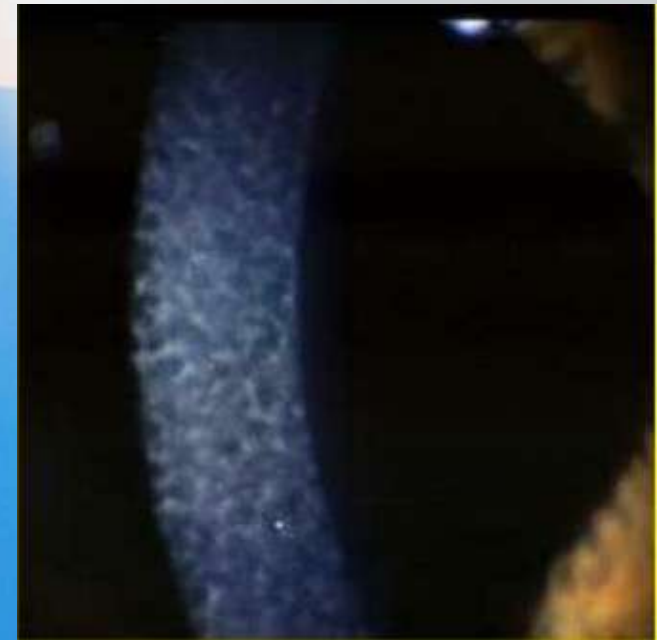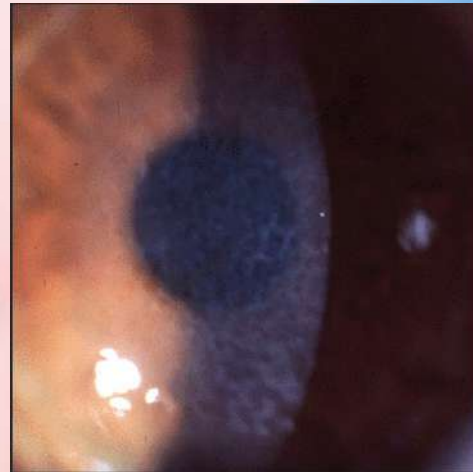*Epithelial/Sub-Epithelial
Dystrophies
Map Dot Fingerprint*

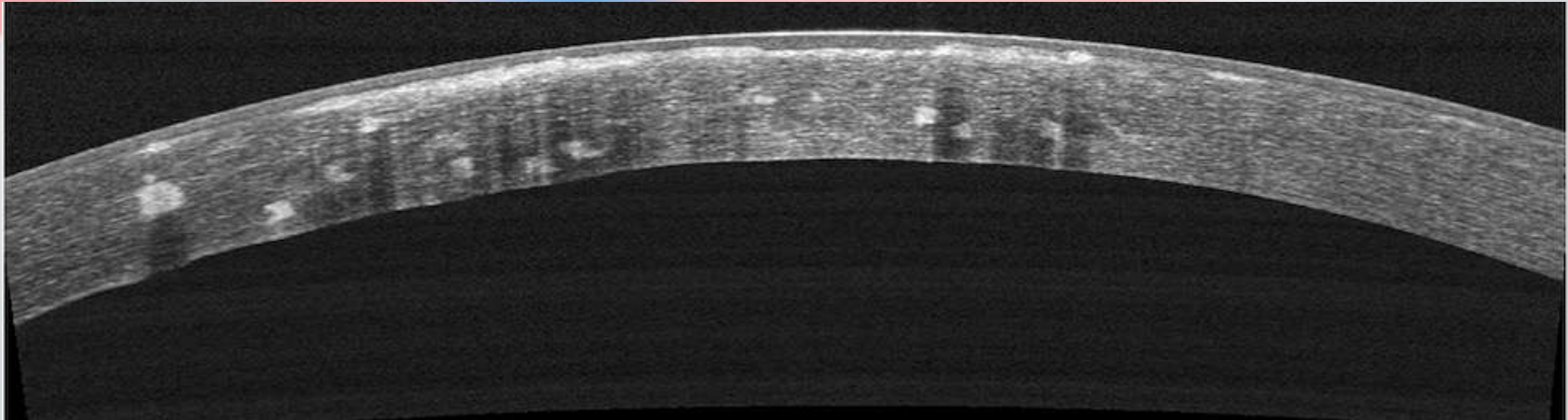




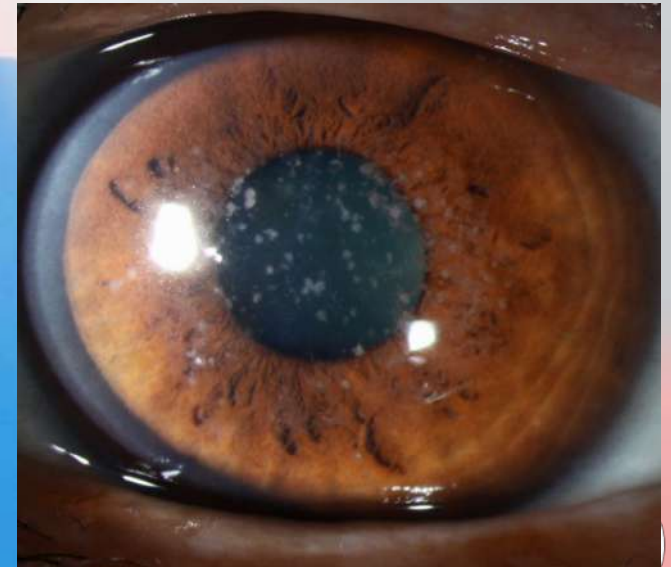
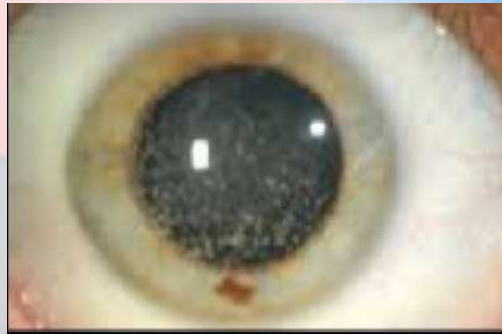Epithelial/Sub-Epithelial Dystrophies

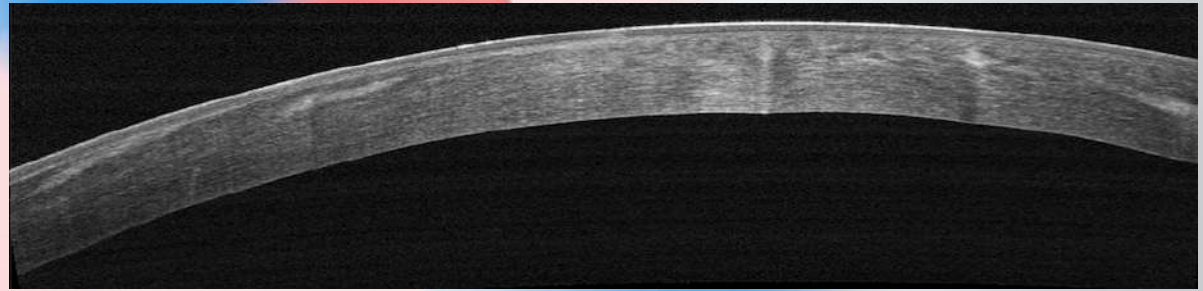
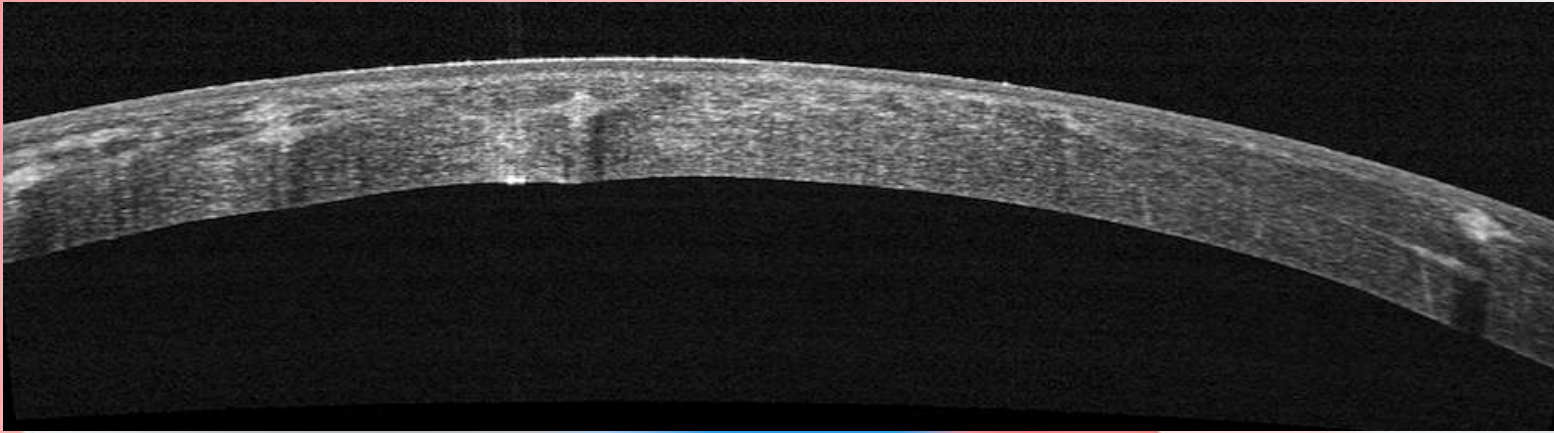
Reis Buckler



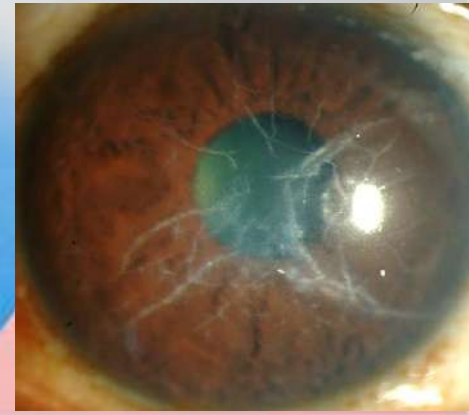
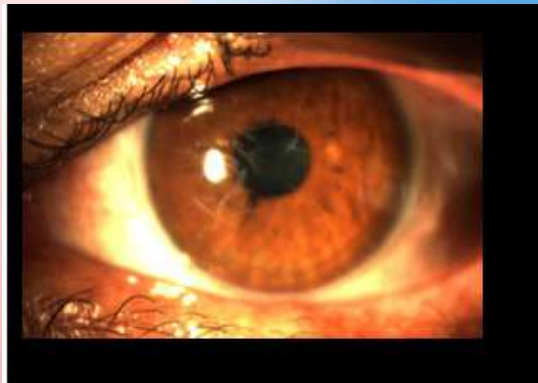
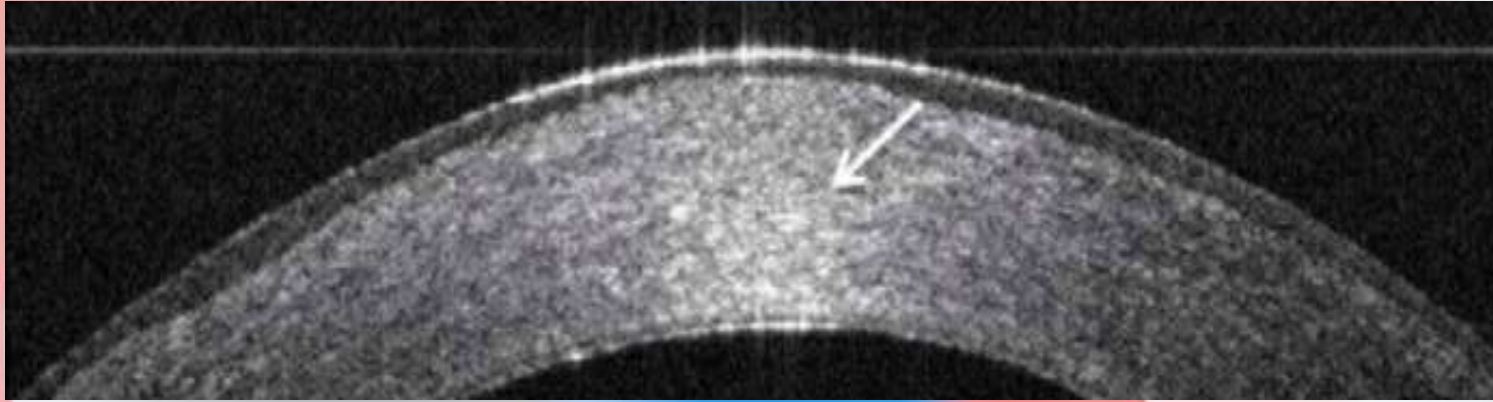
Stromal Dystrophies
Granular





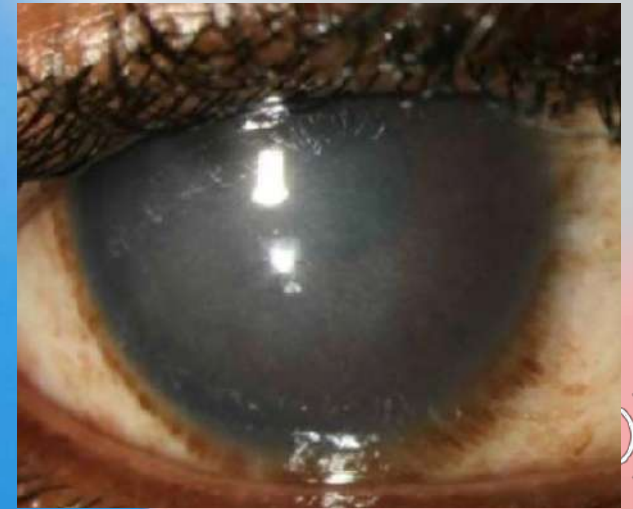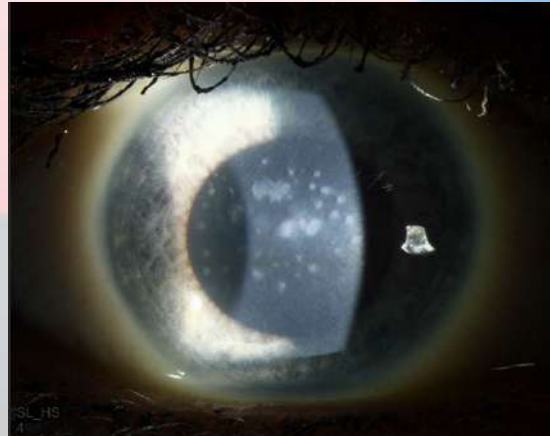
*Stromal
Dystrophies
Lattice*

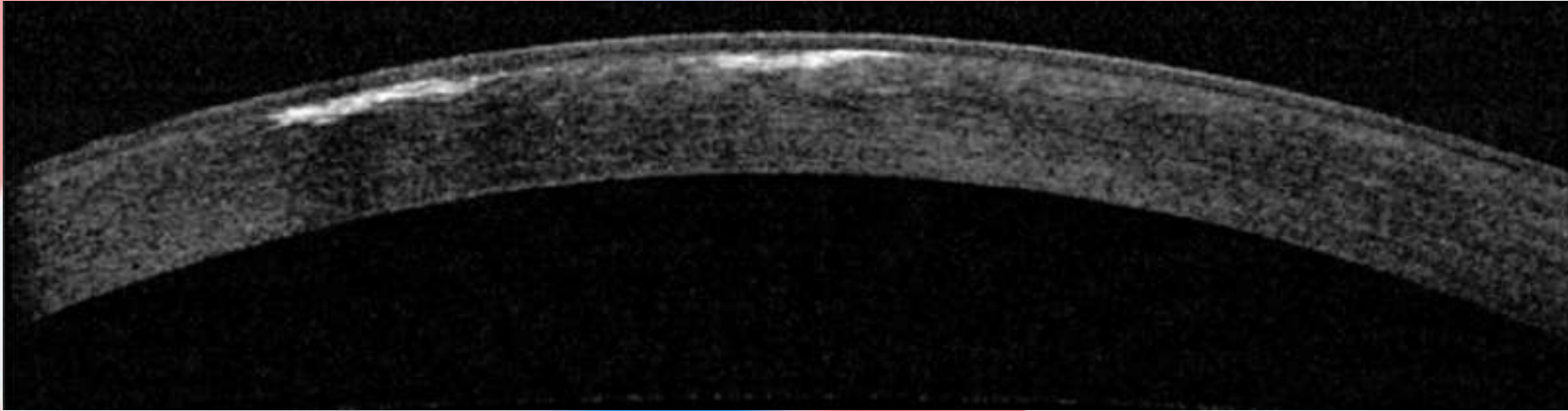




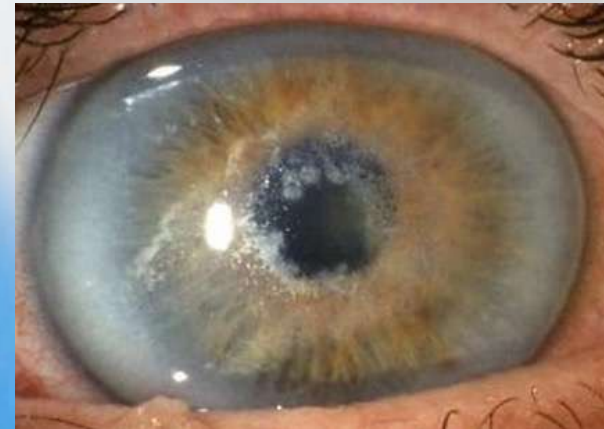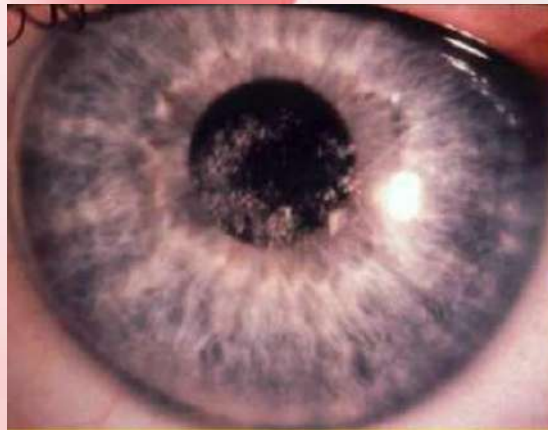
Stromal Dystrophies

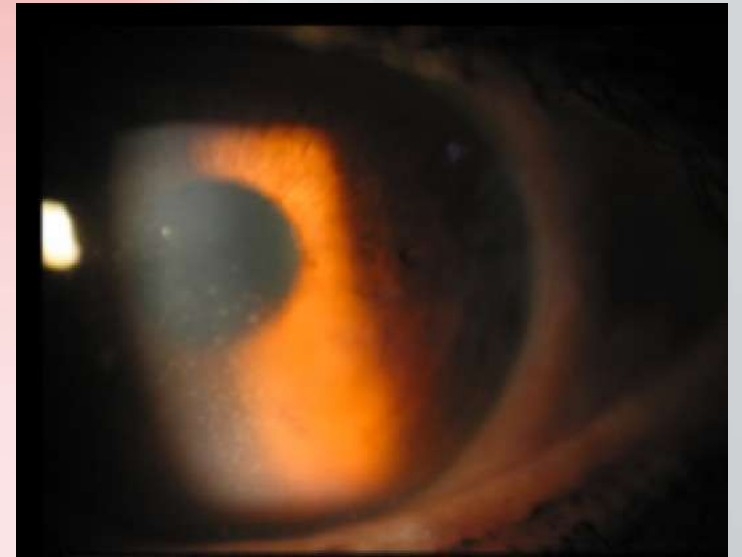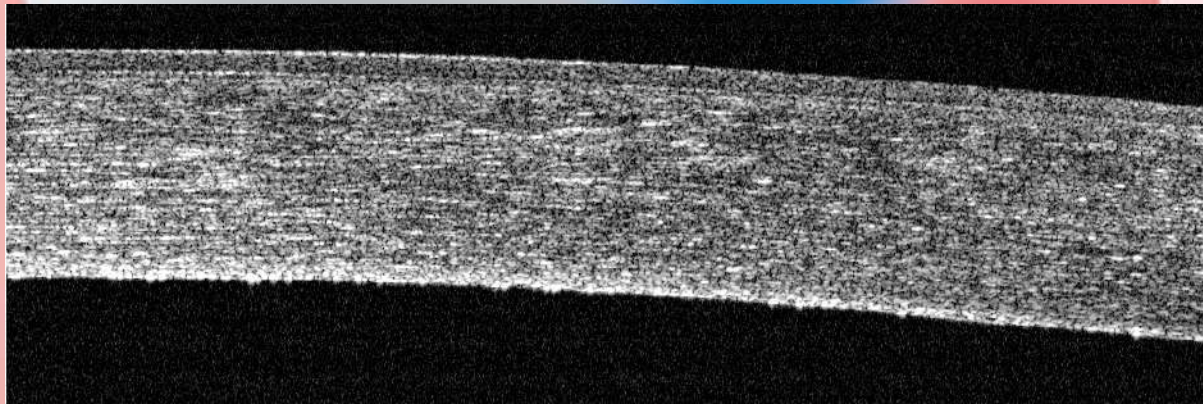
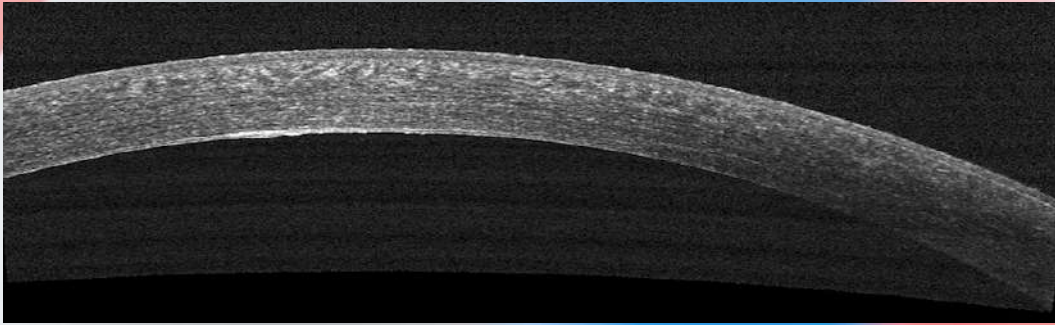
Macular



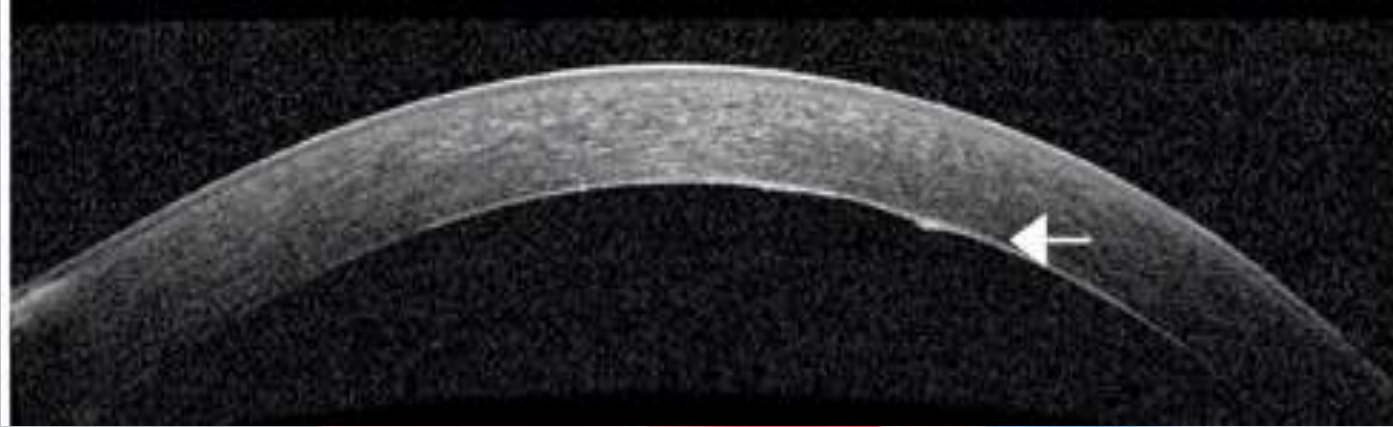


*Stromal
Dystrophies
Schnyder Crystalline*



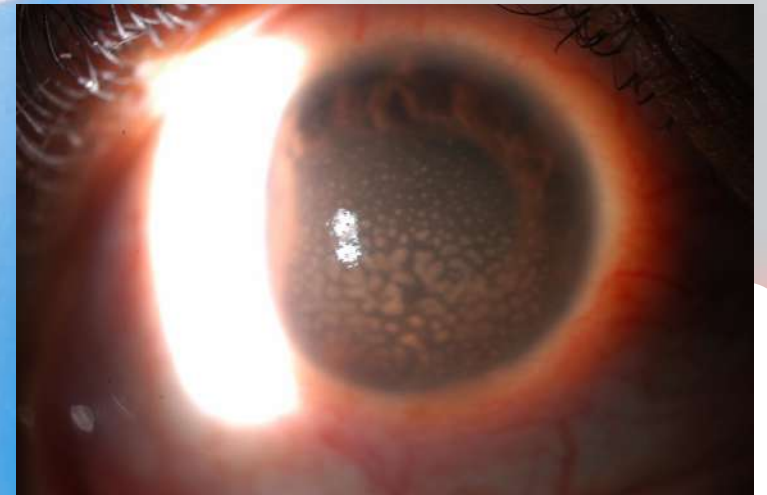
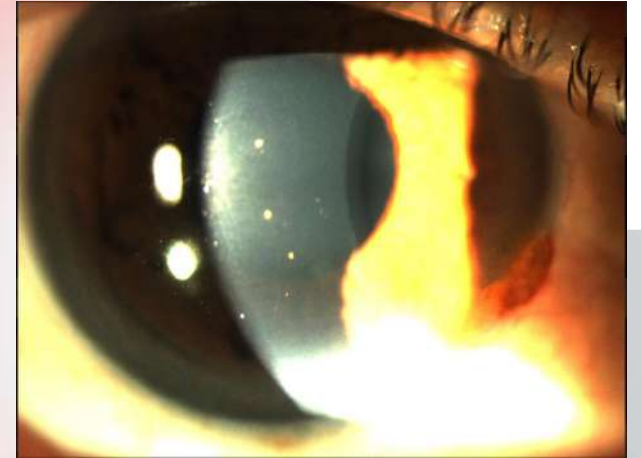
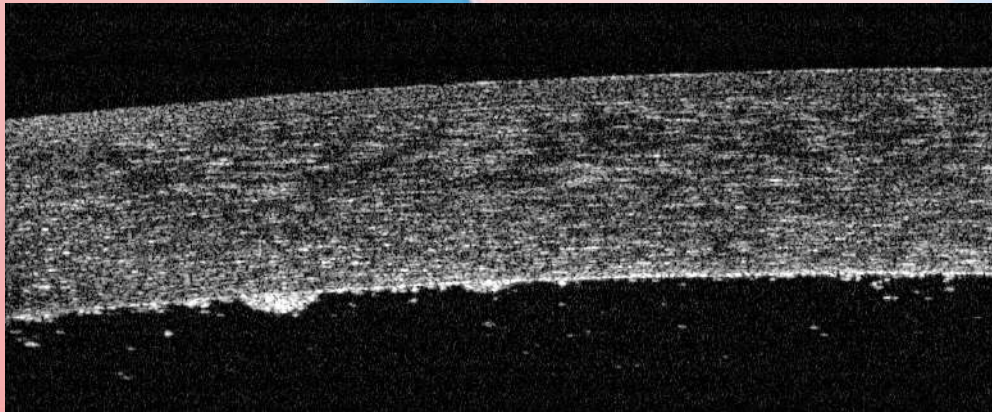
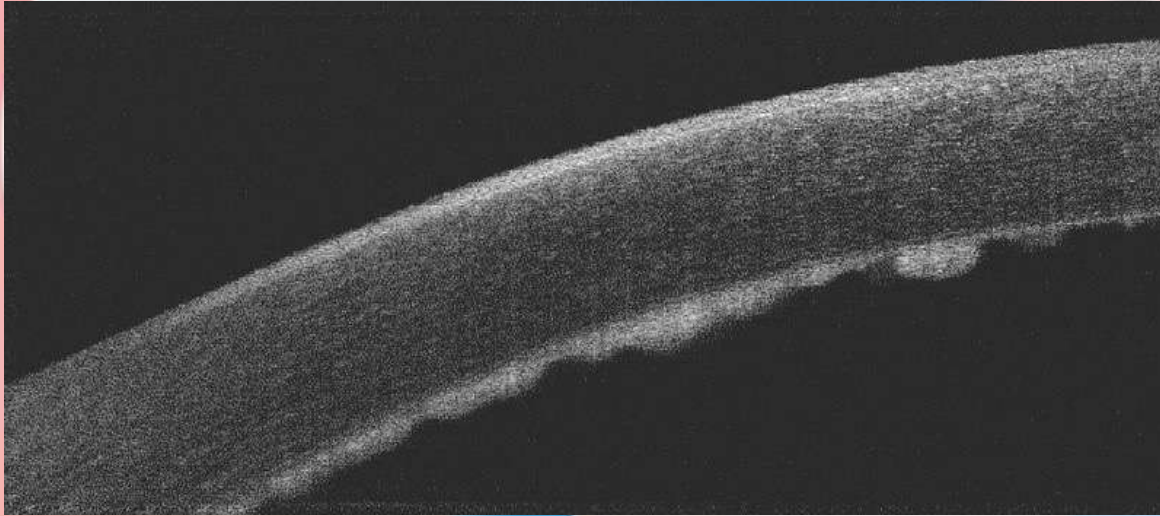


Endothelial Dystrophies
Fuch's Endothelial

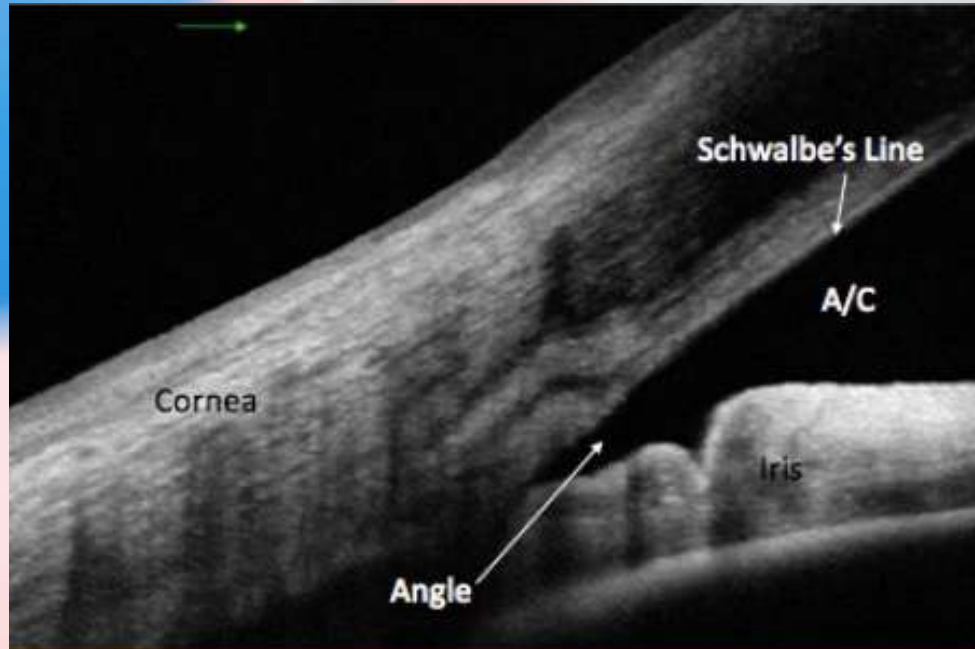


Endothelial Dystrophies
Posterior Polymorphous

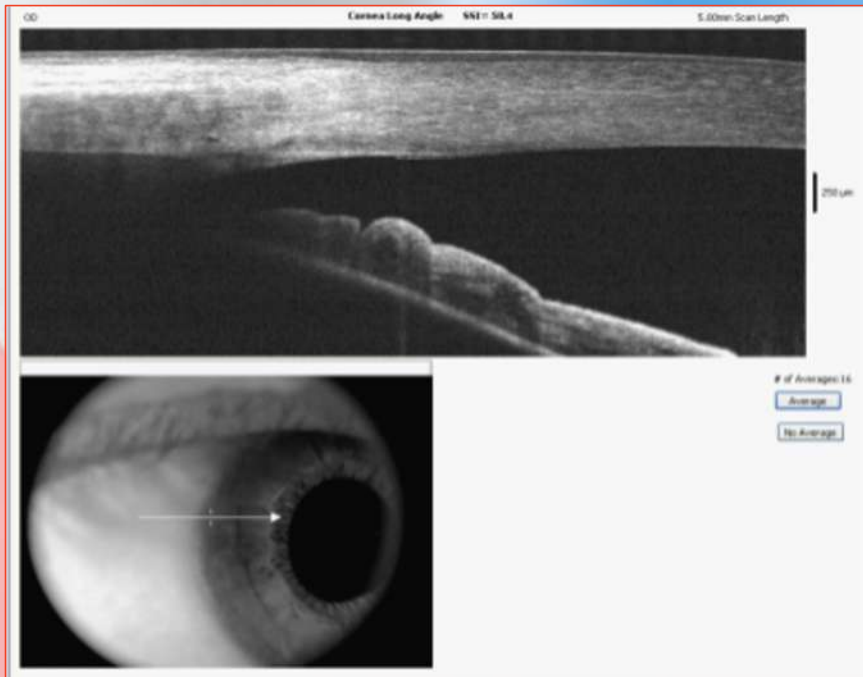
Keratic Precipitates



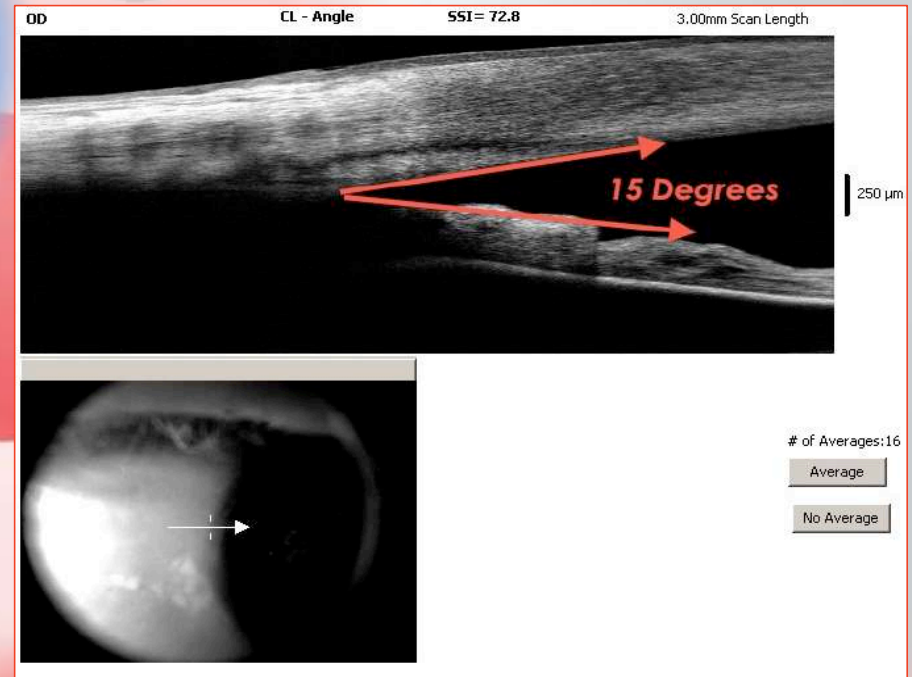
Angle Measurement



Angle Measurement



Normal



Narrow



How narrow is the angle???

Light

Dark

Cornea Angle Comparison Report

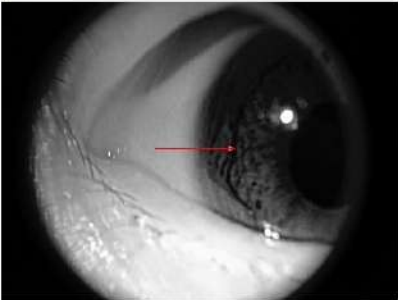
Scan 01/09/2019 11:39:30

Signal Strength Index: 49

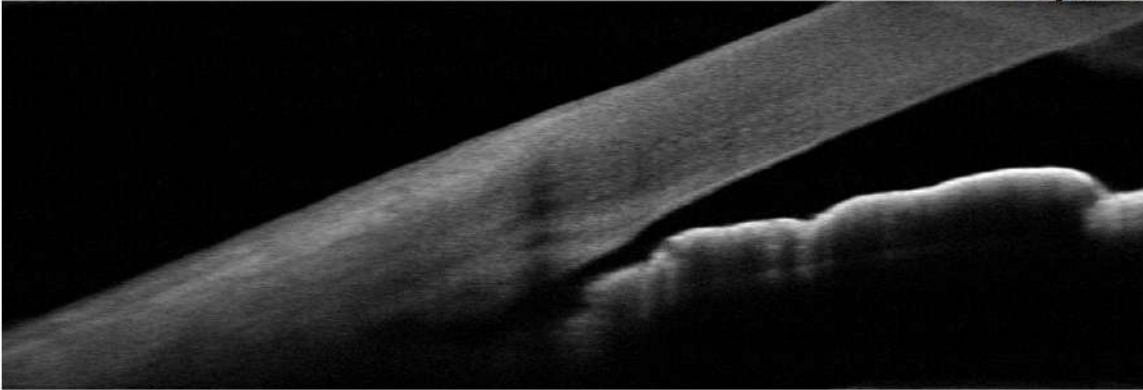
3.00 Scan Size (mm)

Right / OD

IR



250µm




Scan 01/09/2019 11:41:26

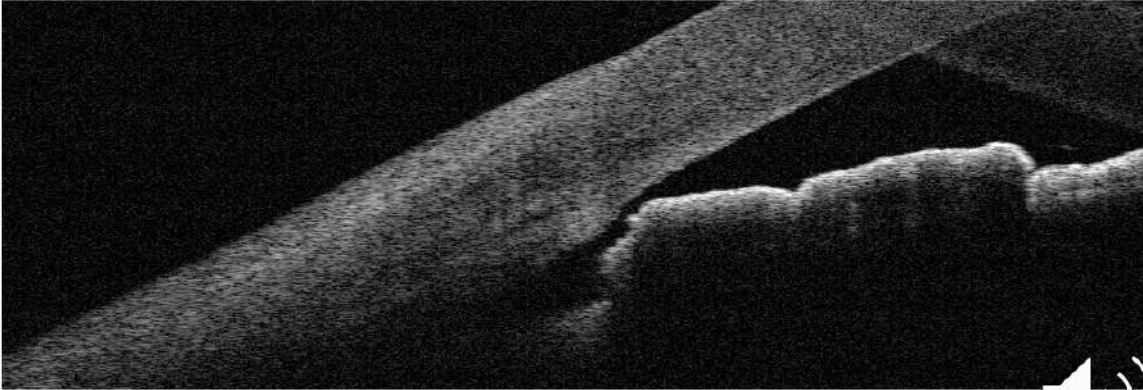
Signal Strength Index: 53

3.00 Scan Size (mm)

IR



250µm



Print

OU Report

Right / OD

OPTOVUE

The background features a light pink-to-white gradient. Scattered across the scene are several semi-transparent circles in shades of blue, red, and white, varying in size. The text is centered in the upper half of the image.

Thank you!!!

rjulie@nova.edu